

## BONE REPAIR OF RABBIT MANDIBULAR TRANSSECTION USING rhBMP-2 AND ATELOCOLLAGEN GEL

A. Kimura<sup>1</sup>, T. Watanabe<sup>2, 5</sup>, T. Shimizu<sup>2, 5</sup>, N. Okafuji<sup>2</sup>, R. Mori<sup>3</sup>, K. Furusawa<sup>3</sup>, T. Kawai<sup>4</sup>, H. Hasegawa<sup>1, 5</sup>, T. Kawakami<sup>5</sup>

<sup>1</sup>Department of Oral Pathology, Matsumoto Dental University School of Dentistry, Shiojiri, Japan

<sup>2</sup>Department of Orthodontics, Matsumoto Dental University School of Dentistry, Shiojiri, Japan

<sup>3</sup>Department of Oral Maxillofacial Surgery, Matsumoto Dental University School of Dentistry, Shiojiri, Japan

<sup>4</sup>Department of Dental Material Science, Aichi-Gakuin University School of Dentistry, Nagoya, Japan

<sup>5</sup>Hard Tissue Pathology Unit, Matsumoto Dental University Institute for Oral Science, Shiojiri, Japan

### Abstract

This experimental was carried out using 12 rabbits. A rabbit experimental mandibular transection was reconstructed with 10 $\mu$ g of rhBMP-2 and 1% atelocollagen gel. The transection gap was fixed with a titanium plate and screws, and covered with poly (lactic-co-glycolic acid) co-polymer (PLGA) membrane. Histopathological examination of 1-week specimens revealed that many spindle cells had proliferated and invaded blood clots, and a small amount of immature trabecular bone was formed in the transection gap. In 2 and 3-week specimens, bone formation was gradually increased in the fibro-vascular tissues of the site. These histological findings were also observed in the control group specimens, but the bone formation was slightly less than in the experimental group. The results suggest the effectiveness of atelocollagen gel as a carrier of rhBMP-2 and PLGA as a covering membrane in this rabbit mandibular transection reconstruction model.

*Key words:* rhBMP-2, atelocollagen, rabbit, mandibular transection, histopathology

### INTRODUCTION

Recombinant human bone morphogenetic protein (rhBMP)-2 plays an important role in bone formation, especially in the healing of bone defects or transection. In general, experiments in the past have been conducted using small-sized animals, such as rats and mice [1-10]. In addition, some experiments have examined bone distraction using middle- to large-sized animals [11-15]. In those reports, the regeneration process was described using rabbits and monkeys. However, bone repair using rhBMP-2 and atelocollagen gel with poly (lactic-co-glycolic acid) co-polymer (PLGA) membrane in rabbit mandibular transection has not been investigated. Therefore, this study was planned.

### MATERIALS AND METHODS

Twelve Japanese white rabbits (Japan SLC Inc., Hamamatsu, Japan) were used. Adult male rabbits, weighing

approximately 1,400g, were maintained in the laboratory for 1 week. The animals were given preoperative doses of intravenous anesthesia. After administration of lidocaine-nebura to the ear skin of the animal for local anesthetic purpose, 1% sodium pentobarbital 25mg/kg was injected intravenously for general anesthetic purpose. Then 1/80,000 epinephrine 2% additive lidocaine 2ml was injected to several locations around the disinfected operative site. The mandibular inferior border was opened, and an incision was made through the masseter muscle and pterygomandibular to the periosteum. The mandibular inferior border periosteum was abraded, and the mandibular bone was segmented (Fig. 1). The animals left mandibular second premolars were transected immediately. After operation, the mandibular segmental gap was fixed with a titanium plate and 4mm diameter screws (Stryker Japan Co, Tokyo, Japan). The transection gap was filled up with 1% atelocollagen gel (Koken Co, Osaka, Japan) containing 10  $\mu$ g of rhBMP-2 (Astellas Pharma Inc., Tokyo, Japan), and covered with a PLGA membrane (GC Co, Tokyo, Japan), whereas the controls were fixed with only a plate and screws (Fig. 2). The periosteum, muscle, and skin were repositioned and closed with silk sutures.

After the operation, the rabbits were medicated using an intramuscular injection of penicillin to minimize the risk of infection in the period from just after the operation to 1 week. In addition, we injected a flurbiprofen axetil for analgesia for 2 weeks. The clinical conditions and food consumption of the animals were monitored. The animals were kept in cages, and were euthanized at intervals of 1, 2 and 3 weeks after operation under intravenous anesthesia. The operation side of the mandible was harvested and immediately fixed in 10% neutral buffered formalin (pH7.0) at room temperature. Samples were decalcified in 10% ethylenediamine tetraacetate (EDTA, pH7.4). Materials were processed and embedded in paraffin. Sections 3  $\mu$ m in thickness were cut longitudinally in the axial plane with a microtome. After sectioning, the specimens were stained with hematoxylin and eosin (H-E) for light microscopy.

The Matsumoto Dental University committee for Animal Experimentation approved the study.

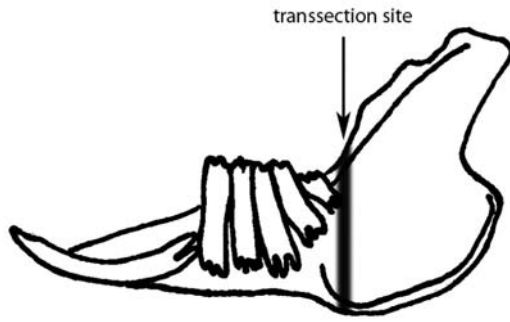


Fig. 1. Schematic diagram of this experimental rabbit mandibular transsection.

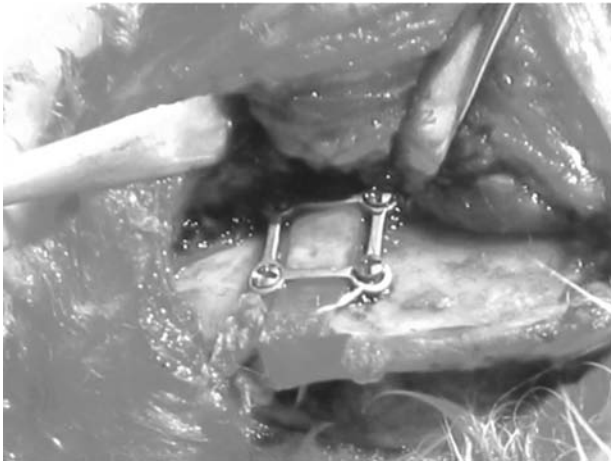

Fig. 2. The gap was fixed using a titanium plate and screws with covering PLGA membrane on mandibular bone.

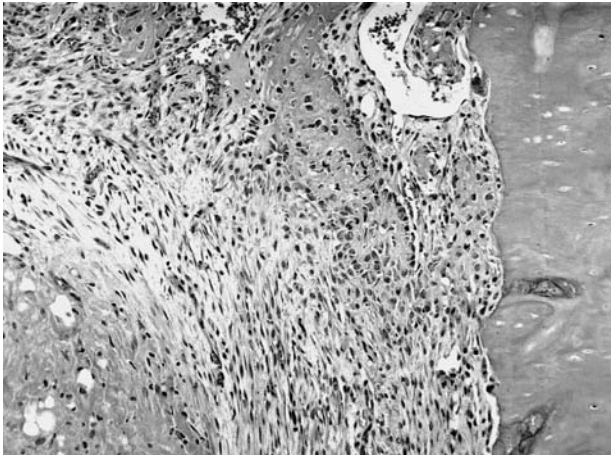


Fig. 3. Blood clots and immature bone formation in the gap (1-week specimen, control group, H-E, x100).

## RESULTS

Regarding the control group, in 1-week specimens, the transsection gap had a large quantity of blood clots with rich fibro-vascular granulation tissues. The granulation tissues with some giant cells appeared inside and

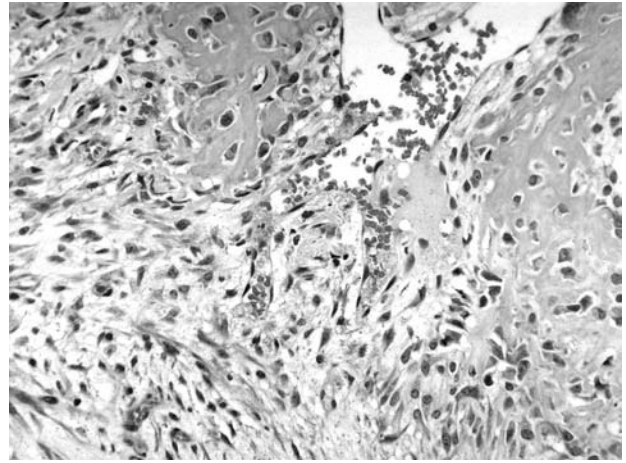


Fig. 4. Enlargement of Fig. 3 showing immature bone formation (1-week specimen, control group, H-E, x200).

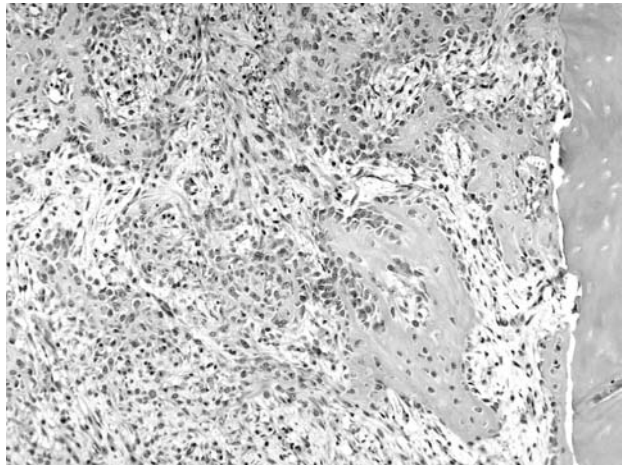


Fig. 5. Spindle shaped cell proliferation and immature bone formation in the gap (1-week specimen, experimental group, H-E, x100).

outside of the blood clots (Fig. 3). In the tissues, a little immature bone had begun to form (Fig. 4). In 2-week specimens, the gap had a mixture of small trabecular bone, some mature, in the granulation tissues. In 3-week specimens, there were a few osteoclasts in the newly formed bone matrix border. Bone remodeling had partially occurred, and mature bone gradually increased. In addition, there were some chondrocytes in the proliferating bone tissues.

Regarding the experimental group, immature bone and numerous proliferating spindle cells were observed (Fig. 5). There was a small amount of blood clots and proliferating spindle cells, including some macrophages, in 1-week specimens (Fig. 6). In 2-week specimens, a mixture of woven bone and maturing lamellar bone with a rich fibro-vascular stroma was observed. In some specimens, small foci of chondrocytes had proliferated in the bony tissues (Fig. 7). In 3-week specimens, there were numerous trabecular mature bone cells (Fig. 8). Chondroid bone in the central part of the gap was evident at this stage.

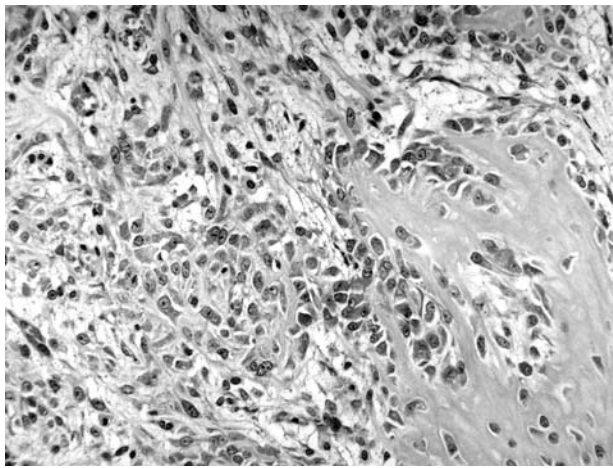


Fig. 6. Enlargement of Fig. 5 showing osteogenic cell increase in a border of immature bone (1-week specimen, experimental group, H-E, x200).

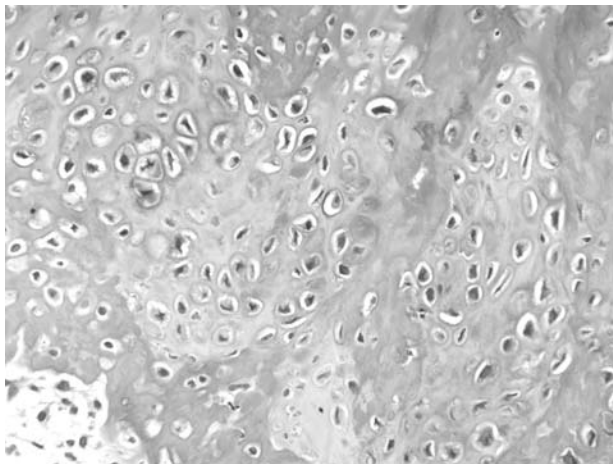


Fig. 7. Localization of chondrocyte-like cells in the matrix (2-week specimen, experimental group, H-E x200).

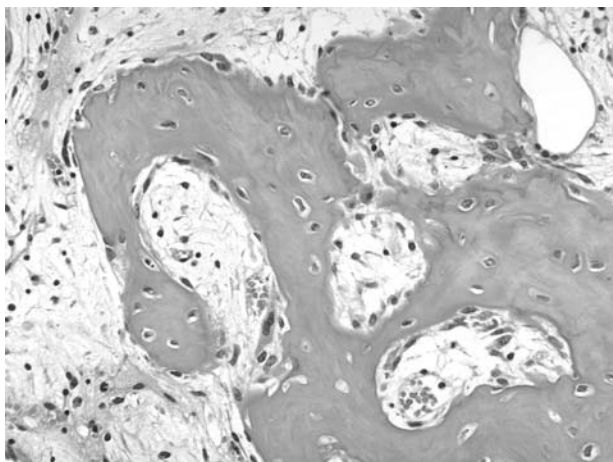


Fig. 8. Newly-formed bone with lamellar structure in the transection gap (3-week specimen, experimental group, H-E, x200).

## DISCUSSION

Loss of bone structures, directly or secondarily-related to neoplasm extirpation, has significant functional and esthetic consequences. This is especially important in the oral and maxillofacial regions, since the recovery of bone defects is a major problem in oral and maxillofacial surgery. Reconstruction of bone defects using rhBMP-2 offers a possible recovery therapy. Thus, there have been many experimental research studies.

Research on the application of BMP for bone formation have induced successful bone defects in experimental animals [1, 2, 6, 8-14]. Nagao et al. reported that rhBMP-2/PGS is an effective bone substitute for reconstructive surgery of the dog mandible [8]. Marukawa et al. showed that the repair of resected bone treated with rhBMP-2 regenerated completely at 12 weeks postoperatively in monkeys [9]. Boyne et al. successfully restored bone in monkey mandibular large defects by hemimandiblectomy using rhBMP-2 [10]. In these experiments, which were carried out in middle-to large-sized animals, comparatively good results were reported. However, the bone healing process of transection or large bone defects is still not fully understood. To augment actin and facilitate fundamental biological research or chemical applications, various chemical compounds have been examined as BMP carriers. The carriers are different in each case in terms of clinical application site and situation.

In our research group, atelocollagen gel as a BMP carrier and PLGA membrane as a covering material were previously examined using a rabbit mandibular bone defect model. According to those results, atelocollagen gel and PLGA composite were effective for recovery of bone defects [11]. Therefore, we conducted this current examination. Regarding the atelocollagen gel, as a carrier for rhBMP-2, are characteristic of atelocollagen is low immunogenicity. Murata et al. indicated that the carrier collagen was gradually replaced by rhBMP-2 presented bone tissue [12]. Our present study demonstrated that the rhBMP-2 increased bone growth in the carrier atelocollagen gel and facilitated the replacement process. These results suggest that a combination of BMP and atelocollagen gel with PLGA does not cause harm in regeneration. Therefore, the combination seems effective as an osteogenic material in middle-sized animals such as rabbits. Our present result showed good recovery of the rabbit mandibular transection defect due to the proliferating osteogenic granulation and osteogenesis.

Regarding the "appearance of chondrocyte-like cells", it is thought that the cell characteristics were similar to those described in our previously research reports [16, 17]. Our research group mentioned that the third ossification mode, "transchondroid bone formation", was displayed in the BMP-induced bone formation model, especially in heterotopic bone. Therefore, in this present examination, the "appearance of chondrocyte-like cells" suggests that the third type of ossification mode, "transchondroid bone formation", occurred in the present rabbit mandibular bone transection model experiment. In other words, it appears as if the "chondrocyte-like cells" caused "chondroid bone". A decrease of oxygen inflow is thought to be

one of the causes. We believe that the difference of the chondroid bone formation range in controls and experiments was due to the presence of BMP. The outside is covered with PLGA around the transection gap and bone formation was affected. It is very likely that caused by decrease of the ingredient necessary. Murata et al. has proposed that a decrease in oxygen inflow affects bone formation [12].

#### REFERENCES

1. Lee SC, Shea M, Battle A, Kozitza K, Ron E, Turek T, Schaub RG, Hayes WC (1994) Healing of large segmental defects in rat femurs is aided by rhBMP-2 in PLGA. *J Biomater Res* 28: 1149-1156.
2. King GN, Cruchley AT, Wozney JM, Hughes FJ (1997) Recombinant human bone morphogenetic protein-2 promotes wound healing in rat periodontal fenestration defects. *J Dent Res* 76: 1460-1470.
3. Huang KK, Shen C, Chiang CY, Hsieh YD, Fu E (2005) Effects of bone morphogenetic protein-6 on periodontal wound healing in a fenestration defect of rats. *J Periodont Res* 40: 1-10.
4. Maki F, Murata M, Kitajo H, Sato D, Taira H, Arisue M (2000) Bone healing large mandibular defects without periosteum in adult rabbits: A new application of collagenous sponge for bone regeneration. *J Hard Tissue Biol* 9: 56-62.
5. Wikesjo UME, Sorensen RG, Kinoshita A, Li XJ, Wozney JM (2004) Periodontal repair in dogs: effect of recombinant human bone morphogenetic protein-12 (rhBMP-12) on regeneration of alveolar bone and periodontal attachment. *J Clin Periodontol* 31: 662-670.
6. Welch RD, Jones AL, Bucholz RW, Reinert CM, Tjia JS, Pierce WA, Wozney JM, Li XJ (1998) Effect of recombinant human bone morphogenetic protein-2 on fracture healing in a goat tibial fracture model. *J Bone Miner Res* 13: 1483-1490.
7. Cheung LK, Zhang Q (2004) Healing of maxillary alveolus in transport distraction osteogenesis for partial maxillectomy. *J Oral Maxillofac Surg* 62: 66-72.
8. Marukawa E, Asahina I, Oda M, Seto I, Alam MI, Enomoto S (2001) Bone regeneration using recombinant human bone morphogenetic protein-2 (rhBMP-2) in alveolar defects of primate mandibles. *Br J Oral Maxillofac Surg* 39:452-459.
9. Nagao H, Tachikawa N, Miki T, Oda M, Mori M, Takahashi K, Enomoto S (2002) Effect of recombinant human bone morphogenetic protein-2 on bone formation in alveolar ridge defects in dogs. *Int J Oral Maxillofac Surg* 31:66-72.
10. Boyne PJ, Nakamura A, Shabahang S (1999) Evaluation of the long-term effect of function on rhBMP-2 regenerated hemimandibulectomy defects. *Br J Oral Maxillofac Surg* 37:344-352.
11. Okafuji N, Shimizu T, Watanabe T, Kimura A, Kurihara S, Arai Y, Furusawa K, Hasegawa H, Kawakami T (2006) Three dimensional observation of reconstruction course of rabbit experimental mandibular defect with rhBMP-2 and atelocollagen gel. *Eur J Med Res* 11(8): 351-354.
12. Murata M, Maki F, Sato D, Shibata T and Arisue M (2000) Bone augmentation by onlay implant using recombinant human BMP-2 and collagen on adult rat skull without periosteum. *Clin Oral Impl Res* 11:289-295.
13. Boussein BML, Turek TJ, Blake CA, Augusta DD, Li X, Stevens M, Seeherman HJ, Wozney JM (2001) Recombinant human bone morphogenetic protein-2 accelerates healing in a rabbit ulnar osteotomy model. *J Bone Joint Surg* 83: 1219-1230.
14. Luppen CA, Blake CA, Ammirati KM, Stevens ML, Seeherman HJ, Wozney JM, Boussein ML (2002) Recombinant human morphogenetic protein-2 enhances osteotomy healing in glucocorticoid treated rabbits. *J Bone Miner Res* 17: 301-310.
15. Takayuki A, Izumi Y, Kazuhiro T, Jinichi F (2002) Effects of latency period in a rabbit mandibular distraction osteogenesis. *Oral Maxillofac Surg* 39: 71-75.
16. Kawakami T, Hiraoka BY, Kawai T, Takei N, Hasegawa H and Eda S (1999) Expression of transforming growth factor-beta peptide and its mRNA in chondrocytes in the early phase of BMP-induced heterotopic "transchondroid bone formation". *Med Sci Res* 27:419-421.
17. Kawakami T, Kawai T, Kimura A, Hasegawa H, Tsujigawa H, Gunduz M, Nagatsuka H, Nagai N (2001) Characteristics of bone morphogenetic protein-induced chondroid bone: histological, immunohistochemical and in situ hybridization examinations. *J Int Med Res* 29: 480-487.

*Received: March 23, 2006 / Accepted: June 16, 2006*

#### *Address for correspondence:*

Akihiro Kimura, PhD, DDS, Assistant Professor  
 Department of Oral Pathology  
 Matsumoto Dental University School of Dentistry  
 1780 Hirooka-Gobara, Shiojiri, 399-0781 Japan  
 Tel.: +81-(0)263-51-2093  
 Fax: +81-(0)263-51-2093  
 E-mail: akihiro@po.mdu.ac.jp