

SURFACTANT PROTEIN B DEFICIENCY CAUSED BY A NOVEL MUTATION INVOLVING MULTIPLE EXONS OF THE SP-B GENE*

F. A. B. A. Schuerman¹, M. Griese², J. P. Gille³, F. Brasch⁴, L. A. Noorduin⁵, A. H. van Kaam¹

¹Department of Neonatology and ⁵Department of Pathology, Emma Children's Hospital, Academic Medical Center, Amsterdam, The Netherlands

²Kinderklinik and Poliklinik, Dr. Von Haunersches Kinderspital, Ludwig-Maximilians University, Munich, Germany

³Department of Clinical Genetics and Human Genetics, VU University Medical Center, Amsterdam, The Netherlands

⁴Institute of Pathology, University Hospital "Bergmannsheil", Bochum, Germany

Abstract

Background: Inability to produce surfactant protein (SP)-B causes fatal neonatal respiratory disease. Homozygosity for a frameshift mutation (121ins2) in the gene encoding SP-B (*SFTPB*) is the predominant but not the exclusive cause of disease.

Objectives: To report a novel mutation in the *SFTPB* gene.

Methods: We analyzed tracheal aspirates, lung tissue obtained by in vivo lung biopsy and DNA from a newborn infant with lethal respiratory failure.

Results: DNA analysis revealed a large homozygous genomic deletion encompassing exon 7 and 8 of *SFTPB* gene, a mutation we described as c.673-1248del2959. The parents were both heterozygous carriers. Analysis of the SP profile in tracheal aspirates and lung tissue by immunohistochemistry, routine and electron microscopy supported the diagnosis of SP-B deficiency and suggested that this large mutation might lead to abnormal routing and processing of proSP-B and proSP-C.

Conclusions: This report shows that SP-B deficiency can also be caused by a multi exon deletion in the *SFTPB* gene and this finding emphasizes the importance of using modern DNA analysis techniques capable of detecting multi exon deletions.

Key words: Surfactant protein B deficiency, *SFTPB* gene, multi exon deletion, surfactant metabolism

mice, showing that the inability to produce SP-B results in lethal respiratory distress [3, 4, 5].

In humans, hereditary SP-B deficiency (OMIM *178640) is a rare autosomal recessive disorder, first described in 1993 [4]. The estimated overall incidence of the most common SP-B mutation, a net 2-bp insertion in exon 4 of *SFTPB* (121ins2) is approximately 0.3 – 1 per 1000 individuals [6]. Affected infants develop severe respiratory disease that clinically and radiographically resembles respiratory distress syndrome often seen in premature infants [7]. However, in contrast to respiratory distress syndrome, respiratory failure caused by SP-B deficiency is rapidly progressive and refractory to all treatment modalities except lung transplantation [8]. Histological examination of affected infants reveals accumulation of protein-rich material filling the distal airspaces, a condition also referred to as congenital pulmonary alveolar proteinosis [4].

SP-B is encoded by a single gene (*SFTPB*), located on the short arm of chromosome 2 and comprises 11 exons. Although 121ins2 accounts for up to two-third of the mutant alleles identified in *SFTPB* [4], over two dozens of other SP-B mutations have been identified so far [5,9,10]. Here we report an infant from Azerbaijan with a typical clinical course for SP-B deficiency, which was found to be based on homozygosity for a novel large genomic deletion in *SFTPB*.

INTRODUCTION

Pulmonary surfactant is a mixture of lipids and specific proteins that lower alveolar surface tension and prevent atelectasis at end-expiration. Four surfactant-associated proteins have been identified: surfactant protein (SP)-A, SP-B, SP-C and SP-D [1]. While the glycoproteins SP-A and SP-D are mainly involved in host defense, the small and hydrophobic SP-B and SP-C play an important role in the metabolism and dynamics of the lipids of pulmonary surfactant. They promote the rapid absorption of phospholipids into the monolayer and the stabilization of the surfactant active film at the air/liquid interface of the alveolus [2]. Especially SP-B seems to play a crucial role in normal surfactant function as indicated by studies in genetically engineered

MATERIALS AND METHODS

CASE REPORT

A 40-week-gestation female infant with a birth weight of 3065 g was spontaneously delivered to a 19 year old woman after an uncomplicated pregnancy. She was the first child of non-consanguineous parents coming from Azerbaijan, with an unremarkable family history. Apgar scores were 9 and 10 at 1 and 5 min, respectively. At few hours of life she was admitted at the pediatric ward of a general hospital because of grunting and cyanosis. Despite supplemental oxygen, continuous positive airway pressure and antibiotics, her clinical condition deteriorated over the next 48 h. She was intubated, mechanically ventilated and transferred to our neonatal intensive care unit. She was treated with high-frequency oscillatory ventilation, requiring a continuous distending pressure of 25 cm H₂O and a fraction

*This study was not financially supported.

of inspired oxygen of 1.0 to maintain adequate oxygenation. Hypotension was treated with intravascular volume support and inotropics. Chest radiography showed a diffuse granular opacities and echocardiography revealed no abnormalities. An evaluation for infection was negative for both bacterial and viral pathogens. Administration of 150 mg/kg exogenous surfactant (Curosurf, Nycomed, Breda, The Netherlands) on day 3 and 6 resulted in a marked, but transient improvement in oxygenation. Despite normalization of the hemodynamic condition, the respiratory status gradually deteriorated in the second week of life. As this clinical course could well be explained by SP-B deficiency, we collected blood from the patient and her parents for DNA analysis, tracheal aspirates for surfactant proteins characterization and performed open lung biopsy on day 17. On day 20 the infant died.

HISTOPATHOLOGY AND ELECTRON MICROSCOPY

A number of small pieces from the open lung biopsy were fixed in Karnovsky's fixative, one slice was snap frozen in liquid nitrogen, and the remainder of the specimen was formalin fixed and paraffin embedded.

ANTISERA AND IMMUNOHISTOCHEMISTRY

The monoclonal antibody PE-10 against SP-A was purchased from Dako (Glostrup, Denmark). Rabbit antiserum against mature SP-B was purchased from Chemicon (Temecula, CA). Polyclonal rabbit antiserum against proSP-B (anti-proSP-B) was kindly provided by S. Hawgood (Department of Pediatrics and Cardiovascular Research Institute, University of California San Francisco, USA). A monoclonal antibody against human SP-B was kindly donated by Dr. Y. Suzuki (Department of Ultrastructural Research, Kyoto University, Japan). Polyclonal antisera against the proSP-C epitopes E¹¹-R²³ (anti-NproSP-C) and G¹⁶²-G¹⁷⁴ (anti-CproSP-C) as well as against proSP-B (anti-proSP-B) had been characterized before [11, 12].

Tissue preparation and immunostaining of lung specimens using antisera was performed as previously

described in detail [11, 12]. Briefly, immunostaining of dewaxed paraffin sections was performed in an automated staining system according to the specifications of the manufacturer (TechMate 500, Dako). The immunoreaction was demonstrated using an APAAP Kit (Dako). Fast Red (Dako) was used as alkaline-phosphatase substrate.

SURFACTANT PROTEIN ANALYSIS

Total protein content of the trachea aspirate samples was determined with the Biorad Protein Assay Kit (Biorad, Richmond, CA). Ten mg of total protein were separated under non-reducing conditions on NuPage 10% Bis-Tris gels using a NOVEX X-cell II Mini-Cell system (Novex, San Diego, CA), and the surfactant proteins and their pro-forms were detected on the PVDF membrane by immunoblot using polyclonal rabbit antisera, as described previously [13].

DNA ANALYSIS

DNA was extracted from peripheral blood by standard techniques. Screening for *SFTPB* mutation 121ins2 was performed by digestion of PCR product of exon 4 with *Sfi*I and separation by agarose gel electrophoresis essentially as described by Tredano et al. [14]. Screening of the entire coding sequence, including intron/exon boundaries of *SFTPB* was performed using primers as described previously [10]. Direct DNA sequencing was subsequently performed using BigDye Terminator (version 3.1) chemistry and analysis on an ABI3100 Genetic Analyzer (Applied Biosystems, Forster City, CA).

RESULTS

HISTOPATHOLOGY AND ELECTRON MICROSCOPY

Routine histology showed variable alveolar septal widening, with edema, an increase in inflammatory cells, histiocytes, and some fibroblasts (Fig. 1). Alveolar epithelial hyperplasia was prominent, with an in-

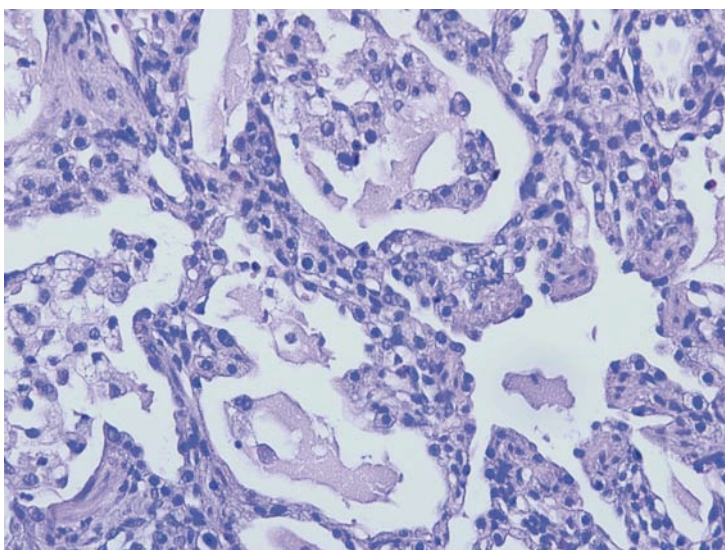


Fig. 1. H&E stained section of open lung biopsy with increased interstitial cellularity, alveolar epithelial hyperplasia, an increase in alveolar macrophages and some intraalveolar proteinaceous material.

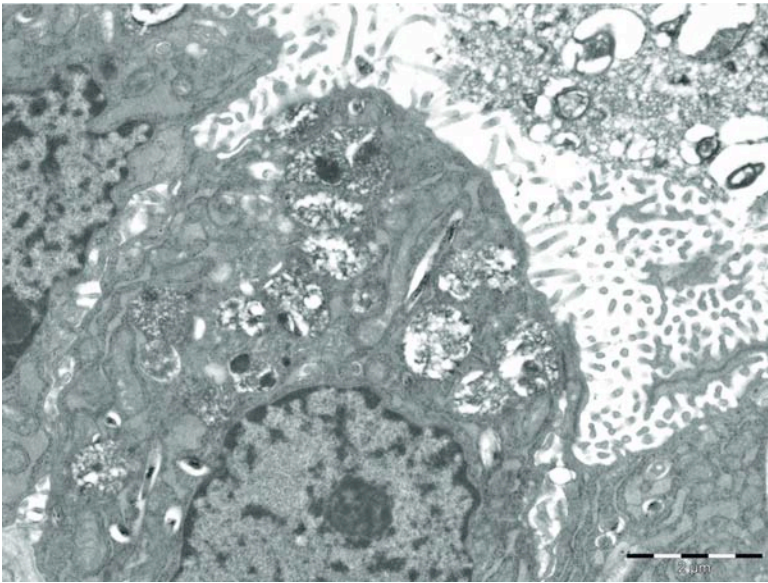


Fig. 2. Electron microscopy of open lung biopsy with type II pneumocyte containing multivesicular bodies.

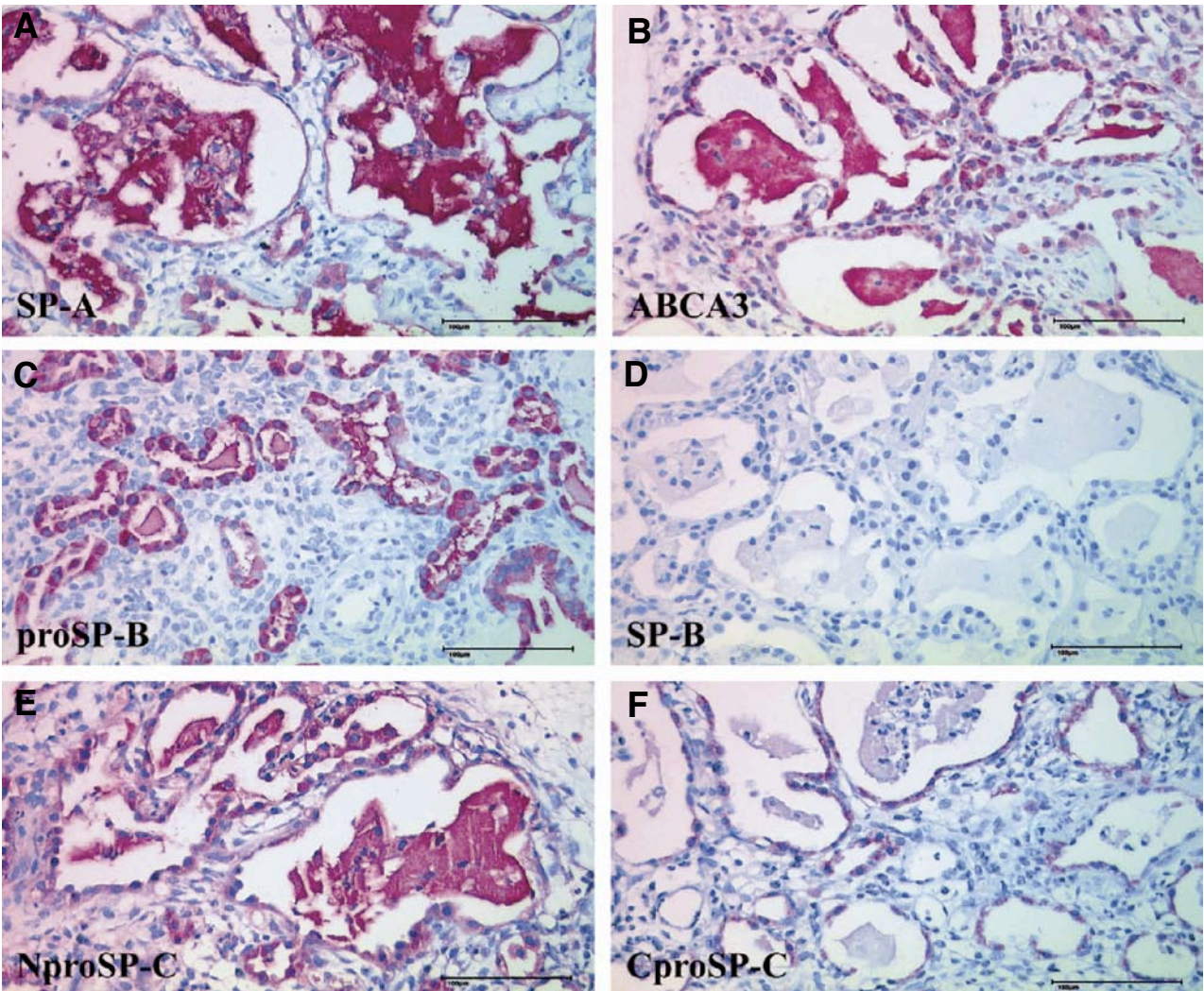


Fig. 3. Immunohistochemistry showed a strong staining of type II pneumocytes and the abnormal intraalveolar surfactant for SP-A (A) and ABCA3 (B). Despite a strong expression of proSP-B (C) in type II pneumocytes, no mature SP-B (D) was detectable. Type II pneumocytes showed a regular expression of the N- (E) and C-terminal (F) propeptide of SP-C (NproSP-C and CproSP-C). The strong staining of the abnormal intraalveolar surfactant for N-terminal insufficiently processed SP-C (E) in combination with a strong staining for ABCA3 (B) but lack of mature SP-B (D) are characteristic findings in patients with hereditary SP-B deficiency.

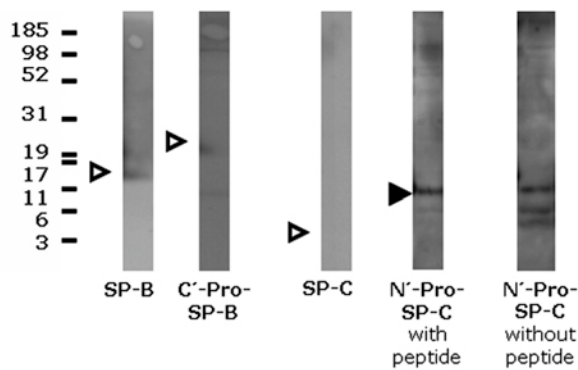


Fig. 4. Western blotting of a tracheobronchial aspirate (10 mg of total protein per lane) of the patient obtained 7 days after exogenous surfactant application. After SDS-PAGE and transfer, the membranes were probed with antibodies against SP-B, pro-SP-B, and SP-C. The pro-forms of SP-C were probed in the absence (without peptide) and presence (with peptide) of an excess of the peptide used to raise this antibody. Molecular weights (kDa) are indicated on the left side. All bands were analyzed under non-reducing conditions. SP-B was detected only in small amounts; no SP-B proforms and no SP-C were detected (open triangles). Aberrant proforms of SP-C were detected at about 12, 8 and 5 kDa. Of these only the bands at 8 and 5 kDa were specifically displaced by competing excess peptide, proving they were authentic. The non-specific band is indicated by the closed triangle.

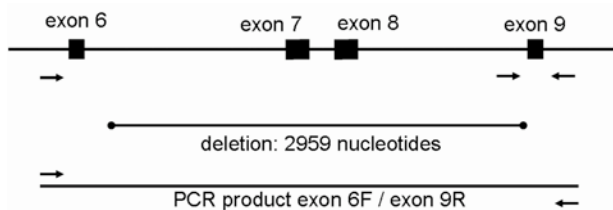


Fig. 5. Schematic representation of part of the *SFTPB* gene (not on scale). Exons are indicated as blocks, introns as lines and PCR primers as arrows. On DNA of the patient, the PCR of the individual exons 7, 8 and 9 failed. Using PCR primers 6 forward and 9 reverse, a product could be obtained of about 1100 bp. This product was sequenced revealing a homozygous deletion of 2959 nucleotides encompassing exon 7 and 8 of *SFTPB* gene. Exon 9 was present, however, the annealing site of the sense primer of exon 9 was within the deletion which explains the failure to produce PCR product for this exon. At the DNA level, the mutation could be described as c.673-1248del2959. This mutation results in the deletion of Gly225 – Lys334 of the proSP-B peptide.

crease in alveolar macrophages and some intraalveolar proteinaceous material.

Ultrastructurally, type II pneumocytes contained abnormal lamellar bodies (Fig. 2). No tubular myelin figures were found in the abnormal intraalveolar surfactant.

IMMUNOHISTOCHEMISTRY

Immunohistochemically, type II pneumocytes and the abnormal intraalveolar surfactant strongly stained for

SP-A and ABCA3 (Fig. 3A and B). Precursors of SP-B were found in type II pneumocytes but staining for mature SP-B was absent (Fig. 3C and D). While, type II pneumocytes showed a regular staining for the N- and C-terminal propeptide of SP-C, N-terminal insufficiently processed precursors were found in the alveolar space (Fig. 3E and F).

SURFACTANT PROTEIN ANALYSIS

Only trace amounts of mature SP-B were found (Fig. 4). No precursors of SP-B and no mature SP-C were identified (open triangles). Aberrant precursors of SP-C were detected at about 12, 8 and 5 kDa. Of these only the bands at 8 and 5 kDa were specifically displaced by competing excess peptide, proving they were authentic.

DNA ANALYSIS

As the initial screening did not reveal a 121ins2 mutation, the entire *SFTPB* gene was screened for other mutations. No product could be obtained by PCR for exon 7, 8 and 9 whereas exon 1-6 and exon 10 gave normal amounts of PCR product. This result suggested a homozygous deletion in this patient. Subsequently, a PCR was performed using the sense primer of exon 6 and the antisense primer of exon 10 resulting in a product of about 1100 bp. DNA sequence analysis of this PCR product showed a deletion of 2959 nucleotides encompassing exon 7 and 8 of SP-B gene. Exon 9 was present, however, the annealing site of the sense primer of exon 9 was within the deletion which explains the failure to produce PCR product for this exon. At the DNA level, the mutation could be described as c.673-1248del2959 (Fig. 5). This mutation results in the deletion of Gly225 – Lys334 of the proSP-B peptide. Normally, proSP-B is converted into the mature SP-B protein which consists of amino acid 201-279. A large part of this amino acid sequence is missing in the presence of this novel mutation. In this patient, the mutation was homozygously present and both parents were heterozygous carriers.

DISCUSSION

Hereditary SP-B deficiency is a rare cause of surfactant dysfunction due to mutations in *SFTPB*, wherein affected newborn infants develop severe rapidly progressive respiratory failure refractory to all treatment modalities. Based on these clinical characteristics, we explored the possibility of hereditary SP-B deficiency in the patient presented in this report.

We first ruled out the most common *SFTPB* mutation 121ins2. Additional analysis showed a homozygous genomic deletion encompassing exon 7 and 8 of the *SFTPB* gene, described as c.673-1248del2959. This mutation results in the deletion of Gly225 – Lys334 of the proSP-B peptide.

Recently the detection rate of disease-causing large genomic rearrangements has increased significantly thanks to the availability of quantitative multiplex PCR-based techniques such as multiplex ligation-dependent probe amplification [15]. Genomic deletions

encompassing 1 or more exons, are well known for many other genes [16]. These deletions are thought to arise by recombination events between intronic repeat elements. In a heterozygous form, these deletions will escape detection by standard PCR-based mutation detection techniques because PCR products will be produced on the remaining normal gene copy on the other chromosome. Furthermore, standard PCR procedures are not quantitative: the amount of PCR product formed will not be significantly less if only 1 copy of the template DNA per genome is present instead of 2 copies per genome. The deletion we have detected in our patient involving more than one exon demonstrates that also the *SFTPB* gene is vulnerable for several or multi exon deletions. Therefore, in patients with SP-B deficiency in which only 1 pathogenic mutation can be detected, alternative methods (such as multiplex ligation-dependent probe amplification, quantitative fluorescent PCR or real time PCR) should be employed to elucidate the second mutation.

Immuno-analysis of the hydrophobic surfactant proteins and their precursors in tracheal aspirates showed small amounts of mature SP-B, absent SP-B proforms and absent SP-C, and aberrant proforms of SP-C. This protein profile is consistent with hereditary SP-B deficiency [13, 17]. The small traces of mature SP-B were most likely residual SP-B from the 2 exogenous surfactant administrations.

Analysis of lung tissue obtained by (in vivo) open lung biopsy showed pulmonary alveolar proteinosis by light microscopy and abnormal lamellar bodies as well as an absence of tubular myelin at the ultrastructural level (Figs. 1 and 2). An absent immunohistochemical staining for mature SP-B combined with a strong staining of the abnormal intracellular surfactant for N-terminal insufficiently processed SP-C by immunohistochemistry, are further supportive of hereditary SP-B deficiency [11, 18].

At the first glance, the expression of proSP-B and proSP-C in type II pneumocytes might be converse to the absence of precursors of SP-B but presence of precursors of SP-C in tracheal aspirates. SP-B is synthesized in type-II-pneumocytes as a 381 amino acid 42 kDa preproprotein. On route from its site of synthesis to the lamellar bodies, the processing to mature SP-B involves the cleavage of the signal peptide, glycosylation of the C-terminus, followed by the cleavage of the N-terminal and C-terminal propeptide [19]. Previously, it has been shown that both, the N-terminal propeptide and the mature peptide are required for proper processing and targeting of SP-B and SP-C to lamellar bodies in type II pneumocytes [20, 21]. Immunohistochemically, the staining for precursors of SP-B in the index patient was confined to intracellular sites of type II pneumocytes, while precursors of SP-C were also detected in the abnormal alveolar surfactant. Thus, abnormal routing and processing of proSP-B and proSP-C might be due to the *SFTPB* mutation which results in a loss of major parts of the mature SP-B peptide and the C-terminal propeptide.

The most important differential diagnosis is hereditary ABCA3-deficiency. Although we did not sequence the *ABCA3* gene, an *ABCA3* mutation is unlikely because a homozygous *SFTPB* mutation fully explains

the biochemical, immunohistochemical, and ultrastructural findings. While *ABCA3* is reduced or absent in newborns with hereditary *ABCA3* deficiency, a strong expression of *ABCA3* in type II pneumocytes and an abnormal intraalveolar accumulation are characteristic findings in newborns with hereditary SP-B deficiency [22].

Just recently, another patient from a different country was reported with a multi-exon SP-B mutation [23]. Although the cases have some similarities, the present report adds important information. First, our report offers more extensive immunohistochemistry, showing normal staining for *ABCA3* and, more importantly, showing absent staining for mature SP-B. Secondly, and in contrast to the previous report, we did not find a truncated form of SP-B in the tracheal aspirates, a finding which seems to be more consistent with the absence of SP-B in immunohistochemistry. Finally, our immunohistochemistry and lavage analysis clearly showed major changes in the metabolism of SP-C, demonstrating the close link between SP-B and SP-C synthesis and supporting the diagnosis SP-B deficiency.

CONCLUSION

In summary, we report a full term newborn with hereditary SP-B deficiency based on a new and large genomic deletion comprising exons 7 and 8 of the *SFTPB* gene that leads to a lack of mature SP-B and SP-C possibly due to an abnormal intracellular routing and processing.

REFERENCES

1. Clark HW, Reid KB, Sim RB: Collectins and innate immunity in the lung. *Microbes Infect* 2000;2:273-278.
2. Whitsett JA, Hull WM, Ohning B, Ross G, Weaver TE: Immunologic identification of a pulmonary surfactant-associated protein of molecular weight = 6000 daltons. *Pediatr Res* 1986;20:744-749.
3. Clark JC, Weaver TE, Iwamoto HS, Ikegami M, Jobe AH, Hull WM, Whitsett JA: Decreased lung compliance and air trapping in heterozygous SP-B-deficient mice. *Am J Respir Cell Mol Biol* 1997;16:46-52.
4. Nogee LM, Garnier G, Dietz HC, Singer L, Murphy AM, deMello DE, Colten HR: A mutation in the surfactant protein B gene responsible for fatal neonatal respiratory disease in multiple kindreds. *J Clin Invest* 1994;93:1860-1863.
5. Nogee LM: Alterations in SP-B and SP-C expression in neonatal lung disease. *Annu Rev Physiol* 2004;66:601-623.
6. Cole FS, Hamvas A, Rubinstein P, King E, Trusgnich M, Nogee LM, deMello DE, Colten HR: Population-based estimates of surfactant protein B deficiency. *Pediatrics* 2000;105:538-541.
7. Farrell PM, Avery ME: Hyaline membrane disease. *Am Rev Respir Dis* 1975;111:657-688.
8. Hamvas A, Nogee LM, Mallory GB, Jr., Spray TL, Hudleston CB, August A, Dehner LP, deMello DE, Moxley M, Nelson R, Cole FS, Colten HR: Lung transplantation for treatment of infants with surfactant protein B deficiency. *J Pediatr* 1997;130:231-239.
9. Lin Z, deMello DE, Batanian JR, Khammash HM, Diangelo S, Luo J, Floros J: Aberrant SP-B mRNA in lung tissue of patients with congenital alveolar proteinosis (CAP). *Clin Genet* 2000;57:359-369.

10. Nogee LM, Wert SE, Proffitt SA, Hull WM, Whitsett JA: Allelic heterogeneity in hereditary surfactant protein B (SP-B) deficiency. *Am J Respir Crit Care Med* 2000;161: 973-981.
11. Brasch F, Birzele J, Ochs M, Guttentag SH, Schoch OD, Boehler A, Beers MF, Muller KM, Hawgood S, Johnen G: Surfactant proteins in pulmonary alveolar proteinosis in adults. *Eur Respir J* 2004;24:426-435.
12. Johnson AL, Braidotti P, Pietra GG, Russo SJ, Kabore A, Wang WJ, Beers MF: Post-translational processing of surfactant protein-C proprotein: targeting motifs in the NH(2)-terminal flanking domain are cleaved in late compartments. *Am J Respir Cell Mol Biol* 2001;24:253-263.
13. Griese M, Schumacher S, Tredano M, Steinecker M, Braun A, Guttentag S, Beers MF, Bahuau M: Expression profiles of hydrophobic surfactant proteins in children with diffuse chronic lung disease. *Respir Res* 2005;6:80.
14. Tredano M, van Elburg RM, Kaspers AG, Zimmermann LJ, Houdayer C, Aymard P, Hull WM, Whitsett JA, Elion J, Griese M, Bahuau M: Compound SFTPB 1549C-->GAA (121ins2) and 457delC heterozygosity in severe congenital lung disease and surfactant protein B (SP-B) deficiency. *Hum Mutat* 1999;14:502-509.
15. Schouten JP, McElgunn CJ, Waaijer R, Zwijnenburg D, Diepvens F, Pals G: Relative quantification of 40 nucleic acid sequences by multiplex ligation-dependent probe amplification. *Nucleic Acids Res* 2002;30:e57.
16. Ferec C, Casals T, Chuzhanova N, Macek M, Jr., Bienvenu T, Holubova A, King C, McDevitt T, Castellani C, Farrell PM, Sheridan M, Pantaleo SJ, Loumi O, Messaoud T, Cuppens H, Torricelli F, Cutting GR, Williamson R, Ramos MJ, Pignatti PF, Raguene O, Cooper DN, Audrezet MP, Chen JM: Gross genomic rearrangements involving deletions in the CFTR gene: characterization of six new events from a large cohort of hitherto unidentified cystic fibrosis chromosomes and meta-analysis of the underlying mechanisms. *Eur J Hum Genet* 2006;14:567-576.
17. Hawgood S, Clements JA: Pulmonary surfactant and its apoproteins. *J Clin Invest* 1990;86:1-6.
18. Schumacher RE, Marrogi AJ, Heidelberger KP: Pulmonary alveolar proteinosis in a newborn. *Pediatr Pulmonol* 1989;7:178-182.
19. Guttentag SH, Beers MF, Bieler BM, Ballard PL: Surfactant protein B processing in human fetal lung. *Am J Physiol* 1998;275:L559-L566.
20. Lin S, Phillips KS, Wilder MR, Weaver TE: Structural requirements for intracellular transport of pulmonary surfactant protein B (SP-B). *Biochim Biophys Acta* 1996; 1312:177-185.
21. Lin S, Akinbi HT, Breslin JS, Weaver TE: Structural requirements for targeting of surfactant protein B (SP-B) to secretory granules in vitro and in vivo. *J Biol Chem* 1996; 271:19689-19695.
22. Brasch F, Schimanski S, Muhlfield C, Barlage S, Langmann T, Aslanidis C, Boettcher A, Dada A, Schrotten H, Mildenerger E, Prueter E, Ballmann M, Ochs M, Johnen G, Griese M, Schmitz G: Alteration of the pulmonary surfactant system in full-term infants with hereditary ABCA3 deficiency. *Am J Respir Crit Care Med* 2006; 174:571-580.
23. Wegner DJ, Hertzberg T, Heins HB, Elmberger G, MacCoss MJ, Carlson CS, Nogee LM, Cole FS, Hamvas A: A major deletion in the surfactant protein-B gene causing lethal respiratory distress. *Acta Paediatr* 2007;96:516-520.

Received: September 6, 2007 / Accepted: February 29, 2008

Address for correspondence:

A. H. van Kaam, MD, PhD.
Department of neonatology (room H3-150)
Emma Children's Hospital AMC
PO Box 22700
1100 DD Amsterdam
The Netherlands
Tel.: +31 20 5663971, Fax: +31 20 6965099
E-mail: a.h.vankaam@amc.uva.nl