

Letter to the Editor

## BRAIN ABSCESS CAUSED BY STREPTOCOCCUS PNEUMONIAE WITH ACUTE ONSET AND RAPID PROGRESSIVE SYMPTOMS

H.-J. Gdynia, A. Unrath, C. Palm, R. Huber

University of Ulm, Department of Neurology, Ulm, Germany

### Abstract

Although the decline of the morbidity and mortality in recent years, brain abscess is still an important problem in neurocritical care medicine and remains a serious illness that can result in severe disability or even death, especially if misdiagnosed or managed improperly. We report a very rare case of a patient who developed a bacterial brain abscess in the posterior fossa with an atypical rapid progression of neurological symptoms. Furthermore, MRI demonstrated additional brain stem and left hemispheric lesions. Early onset broad antibiotic therapy, corticosteroid application and extensive intermediate care management was leading to a complete regression of the initially dramatic symptoms.

*Key words:* brain abscess, pneumonia, streptococcus pneumoniae, antibiotic therapy

### TO THE EDITOR

A 41 years old woman presented with mild fever and cough, chest x-ray revealed typical lobar pneumonia. Personal and familial history showed no abnormalities, no evidence for immunocompromised conditions. Initially neurological symptoms were not present. Due to the mild presentation of symptoms, an ambulant oral cephalosporin therapy was initiated. One day later the patient presented with a progressive reduction of vigilance in our intermediate care unit. Neurological examination demonstrated an initially low grade, but very rapid progressive paresis of the right upper and lower extremities, furthermore palsies of the left cranial nerves III and VII. Routine laboratory investigations showed no abnormalities, especially no leucocytosis or elevation of c-reactive-protein. Bacterial culture for blood was unremarkable, culture for sputum revealed *Streptococcus pneumoniae*. Contrast enhanced MRI demonstrated a brain abscess with ring-shaped contrast enhancement in the left pontine cerebellar angle, furthermore massive brainstem and left hemispheric oedema in the FLAIR (Fig. 1) and T2 sequences. There was no evidence for intracranial pressure and midline shift, so a surgical decompression was not enforced. CSF analysis demonstrated 299 cells/ $\mu$ l (90% neutrophil leucocytes) and increased protein of 1692 mg/l. The gram staining revealed gram-positive cocci, microbiological analysis proofed *Streptococcus pneumoniae*. An intravenous antibiotic

therapy with ceftriaxone, vancomycin and metronidazole was initiated, furthermore therapy with dexamethasone. CSF re-evaluation 5 days after therapy onset revealed 1 cell/ $\mu$ l and 539 mg/l protein, furthermore no evidence for cocci. Neurological re-examinations showed a consecutive increasing level of consciousness and reduction of the hemiparesis and cranial nerve palsies. All neurological symptoms remitted completely 8 weeks after therapy onset, MRI demonstrated a nearly complete regression of the lesions.

Brain abscesses still keep their importance with a high mortality and morbidity despite the improvement in diagnosis and treatment modalities in recent decades [1, 2]. In a recent study with 178 patients, viridans group Streptococci were the most frequently encountered pathogens, followed by Peptostreptococcus and Staphylococcus. The authors found haematoge-

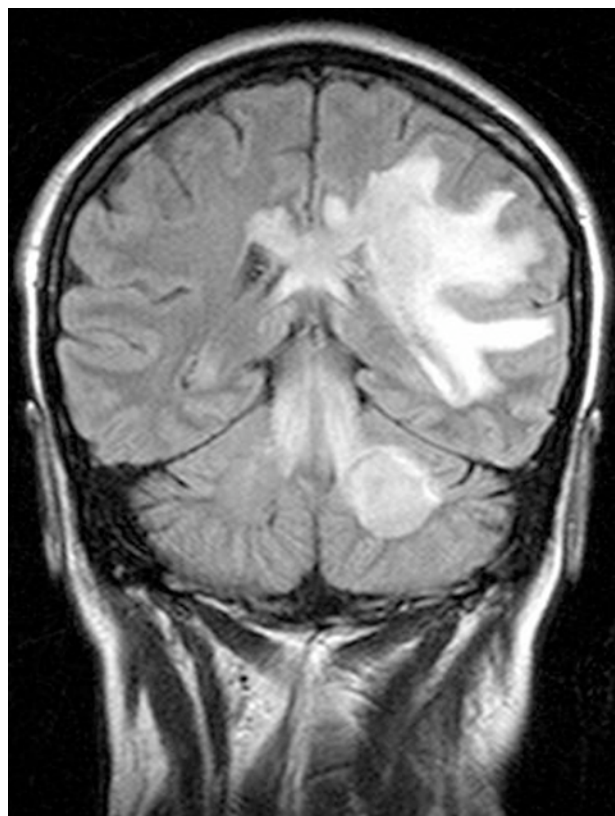


Fig. 1. Cerebral MRI (FLAIR).

nous spread as the most common cause of brain abscess in their patients, 12% of the patients presented with immunocompromised conditions like acquired immunodeficiency syndrome [3]. Jorens and colleagues mentioned *Streptococcus pneumoniae* as a common cause of bacterial meningitis but only rarely of other infections like brain abscess. Focused on neuroradiologic features, they reported three adult patients with meningoencephalitis caused by *Streptococcus pneumoniae*. Magnetic resonance imaging demonstrated widespread brain lesions in all patients, suggesting extensive parenchymal injury. Diffusion-weighted images revealed regions with restricted diffusion, reflecting local areas of ischemia with cytotoxic oedema. A treatment with puls doses of glucocorticoides resulted in an excellent final recovery of their patients [4]. Hakan et al. found 78% of their patients to have predisposing factors [5]. However, our patient showed no immunocompromised conditions and presented with a bacterial brain abscess, caused by haematogenous spread of *Streptococcus pneumoniae*. The initial oral cephalosporin therapy may have caused the negative bacterial culture for blood. The gram staining and the microbiological CSF analysis led to an early detection and differentiation of *Streptococcus pneumoniae*. In this case, a very atypical acute onset and rapid progression of neurological symptoms were seen. The deterioration of the neurological status in our patient was probably caused by rupture of the abscess into ventricles, which could be supported by the positive CSF findings. Striking features are the brainstem and left hemispheric oedemas, which are probably caused by an intracerebral bacterial spread. Early onset intravenous broad antibiotic therapy, corticosteroid application and extensive intermediate care management was leading to a complete regression of the initially dramatic and progressive symptoms. Recently, a prospective randomised, double-blind trial of dexamethasone therapy in bacterial meningitis was performed. Compared with placebo, the treatment with dexamethasone was associated with a significant reduction in mortality. The subgroup analysis demonstrated that dexamethasone was protective only for patients with *Streptococcus pneumoniae* meningitis [6]. Yildizhan et al. demonstrated, that dexamethasone impaired the lymphocytic and fibroblastic responses and delayed the collagen deposition in brain abscesses in

rats [7]. The corticosteroid effect progressively diminishes when the inflammatory lesion encapsulates over time [8]. Beside of corticosteroid administration, early diagnosis [9] and adequate antibiotic therapy are the essential factors to lower the complications and to increase the survive ratio.

#### REFERENCES

1. Mathisen GE, Johnson JP. Brain Abscess. *Clin Infect Dis* 1997;25:763-81.
2. Mampalam TJ, Rosenblum ML. Trends in the management of bacterial brain abscesses: A review of 102 cases over 17 years. *Neurosurgery* 1988;23:451-7.
3. Xiao F, Tseng MY, Teng LJ, Tseng HM, Tsai JC. Brain abscess: clinical experience and analysis of prognostic factors. *Surg Neurol* 2005;63:442-9; discussion 449-50.
4. Jorens PG, Parizel PM, Demey HE, Smets K, Jadoul K, Verbeek MM, Wevers RA, Cras P. Meningoencephalitis caused by *Streptococcus pneumoniae*: a diagnostic and therapeutic challenge. Diagnosis with diffusion-weighted MRI leading to treatment with corticosteroids. *Neuroradiology* 2005;47:758-64.
5. Hakan T, Ceran N, Erdem I, Berkman MZ, Goktas P. Bacterial brain abscesses: An evaluation of 96 cases. *J Infect* 2005 Sep 22; [Epub ahead of print].
6. De Gans J, van de Beek D. Dexamethasone in adults with bacterial meningitis. *N Engl J Med* 2002;347:1549-56.
7. Yildizhan A, Pasaoglu A. Effect of dexamethasone on various stages of experimental brain abscess. *Acta Neurochir* 2005;96:141-148.
8. Lyons BE, Enzmann DR, Britt RH, Obana WG, Placone RC, Yeager AS. Short term, high dose corticosteroids in computed tomographic staging of experimental brain abscess. *Neuroradiology* 1982;23:279-284.
9. Garvey G. Current concepts of bacterial infections of the central nervous system. *J Neurosurg* 1983;59:735-44.

*Received: July 16, 2006 / Accepted: February 26, 2007*

#### *Address for correspondence:*

Hans-Jürgen Gdynia, M.D.  
University of Ulm, Dept. of Neurology  
Oberer Eselsberg 45, 89081 Ulm  
Phone: +49-731-177-5225  
Fax: +49-731-177-1202  
Email: hans-juergen.gdynia@uni-ulm.de