

ACUTE PANCREATITIS AND THROMBOTIC THROMBOCYTOPENIC PURPURA*

I. P. Bergmann¹, J. A. Kremer Hovinga², B. Lämmle², H. J. Peter^{†3}, U. Schiemann³

¹Department of Nephrology and Hypertension,

²Department of Haematology and Central Haematology Laboratory,

³Department of General Internal Medicine,
Inselspital, University of Bern, Bern, Switzerland

Abstract

Thrombotic thrombocytopenic purpura (TTP) has multiple clinical manifestations and risk factors, but the events that actually trigger acute episodes of TTP are often unclear. We describe the case of a 56-year-old woman who presented with clinical signs and symptoms of TTP and acute pancreatitis. We discuss whether pancreatitis was due to ischemic pancreatic damage caused by microvascular platelet clumping in the frame of TTP, or whether acute pancreatitis, a disorder that results in an intense systemic inflammatory response, may be a triggering event for acute episodes of TTP.

INTRODUCTION

Thrombotic thrombocytopenic purpura (TTP) has multiple clinical manifestations and risk factors [1]. The pathogenesis in many patients may involve deficiency of ADAMTS 13, but the events that actually trigger acute episodes of TTP are often unclear [2].

The pancreas is an organ frequently and severely involved in patients with TTP [3, 4], and pancreatic ischemia caused by TTP may contribute to the common symptom of abdominal pain. However, few cases in the literature suggest that the reverse of this sequence may also occur, that pancreatitis may trigger an acute episode of TTP [5].

CASE REPORT

We report the case of a 56-year-old woman, who presented to our hospital with a 3-day history of severe epigastric pain radiating to the back. Her medical record was remarkable for a 12-year history of subacute cutaneous lupus erythematosus. An abdominal CT-scan (Fig. 1) showed signs of exsudative pancreatitis. Laboratory signs of pancreatitis were elevated serum amylase (265 U/l) and lipase (521 U/l). Further laboratory analysis showed a severe thrombocytopenia ($11 \times 10^9/l$), microangiopathic haemolytic anaemia (haemoglobin 76 g/l) with prominent red cell fragmentation (schistocytes) on the peripheral blood smear, a negative direct antiglobulin (Coombs') test,

elevation of indirect bilirubin (28 $\mu\text{mol/l}$) and lactate dehydrogenase (1984 U/l), very low level of haptoglobin (<0.09 g/l), and mild renal insufficiency (creatinine 104 $\mu\text{mol/l}$ and blood urea nitrogen 9 mmol/l). Based on these typical laboratory findings, we diagnosed acute TTP associated with pancreatitis. The activity of the von Willebrand factor (VWF)-cleaving protease (ADAMTS 13) was severely deficient ($<3\%$) in the presence of high titers of non-inhibitory anti-ADAMTS 13 autoantibodies. Initial treatment consisted of daily plasma exchange with fresh frozen plasma replacement in combination with administration of

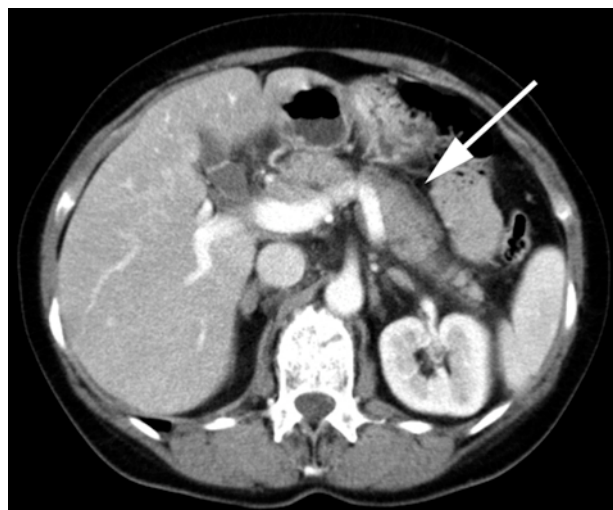


Fig. 1. Abdominal CT scan showing signs of exsudative pancreatitis with diffuse enlargement and irregular contour of the pancreas as well as peripancreatic fluid collections (arrow).

corticosteroids (oral prednisone 2 mg/kg per day). After 6 plasma exchange sessions, platelet count and lactate dehydrogenase normalized and all clinical signs and symptoms of acute pancreatitis and TTP remitted.

CONCLUSION

TTP is a life-threatening disorder characterized by microangiopathic haemolytic anaemia and thrombocytopenia as a result of microvascular platelet clumping often accompanied by ischemic organ dysfunctions such as neurological abnormalities or renal insufficien-

*The paper is dedicated to the memory of H. J. Peter

cy, and fever. In most cases of idiopathic TTP, severe deficiency of ADAMTS 13 prevents processing of unusually large VWF multimers released from endothelial cells. The persistence of unusually large VWF multimers seems to be responsible for the formation of microvascular platelet thrombi. In adults, severe ADAMTS 13 deficiency is often caused by inhibitory ADAMTS 13 autoantibodies. Currently, plasma exchange with replacement of fresh frozen plasma remains the treatment of choice in any patient presenting with acute TTP. The finding of severe autoantibody-mediated ADAMTS 13 deficiency in a relevant number of patients provides the rationale for the concurrent prescription of corticosteroids although their value in this situation is unproven [2, 6].

The possibility of coincidental occurrence of pancreatitis and TTP is very low. It can be estimated from the annual incidence of idiopathic TTP (5 per 10^6 population) and the annual incidence of episodes of pancreatitis in the USA (750 per 10^6 population) [5]. Based on these data, the expected incidence of coincidental occurrence of both disorders within the same year is 3.75 per 10^9 population. It would be even less likely for TTP to occur by chance simultaneously with acute pancreatitis.

It is common that TTP severely affects the pancreas. In a post mortem study, Hosler et al. found pancreatic involvement in 30 out of 51 cases diagnosed with TTP. The mechanism for pancreatic injury during TTP is thought to be impairment of pancreatic circulation by thrombotic occlusion of small vessels and subsequent ischemia [4].

On the other hand, the acute inflammatory response to pancreatitis may trigger the onset of TTP. Swisher et al. reported five patients and reviewed 16 cases from the literature, in which acute pancreatitis preceded clinical and laboratory signs of TTP by a median of 3 days [5]. One postulated mechanism involves diffuse endothelial injury mediated by inflammatory cytokines that are released as part of the systemic inflammatory response to acute pancreatitis. It has been demonstrated in *in vitro* studies that inflammatory cytokines stimulated endothelial cell release of ultralarge VWF multimers and inhibited the cleavage of ultralarge VWF by ADAMTS 13 [7].

Pathophysiologically it cannot be decided whether pancreatitis in our case was due to ischemic pancreatic damage caused by microvascular platelet clumping in the frame of TTP, or whether acute pancreatitis triggered TTP. However, early recognition of TTP and its association with acute pancreatitis is imperative, because prompt treatment with daily plasma exchange combined with administration of corticosteroids can be life saving.

REFERENCES

1. George JN. Thrombotic thrombocytopenic purpura. *New Eng J Med* 2006;354:1927-35.
2. Lämmle B, Kremer Hovinga JA, Alberio L. Thrombotic thrombocytopenic purpura. *J Thromb Haemost* 2005; 3(8):1663-75.
3. Ridolfi RL, Bell WR. Thrombotic thrombocytopenic purpura. Report of 25 cases and review of the literature. *Medicine* 1981;60:413-28.
4. Hosler GA, Cusumano AM, Hutchins GM. Thrombotic thrombocytopenic purpura and hemolytic uremic syndrome are distinct pathologic entities. A review of 56 autopsy cases. *Arch Pathol Lab Med* 2003;127:834-9.
5. Swisher KK, Doan JT, Vesley SK, Kwaan HC, Kim B, Lämmle B, et al. Pancreatitis preceding acute episodes of thrombotic thrombocytopenic purpura-hemolytic uremic syndrome: report of five patients with a systematic review of published reports. *Haematologica* 2007;92:936-43.
6. Moake JL. Thrombotic microangiopathies. *N Engl J Med* 2002;347(8):589-600.
7. Bernardo A, Ball C, Nolasco L, Moake JF, Dong JF. Effects of inflammatory cytokines on the release and cleavage of the endothelial cell-derived ultralarge von Willebrand factor multimers under flow. *Blood* 2004;104:100-6.

Received: July 2, 2008 / Accepted: September 8, 2008

Address for correspondence:

PD Dr. med. Uwe Schiemann
Klinik und Poliklinik für Allgemeine Innere Medizin
Inselspital, University of Bern
Freiburgstrasse 10
CH-3010 Bern, Switzerland
Tel.: +41-31-632 25 25
E-mail: uwe.schiemann@insel.ch