

GRANULOMATOUS MYOSITIS MIMICKING SLOWLY PROGRESSIVE LOWER MOTOR NEURON DISEASE

H.-J. Gdynia, N. Osterfeld, J. Dorst, A. C. Ludolph, C. A. von Arnim, A.-D. Sperfeld

Department of Neurology, University of Ulm, Ulm, Germany

Abstract

Here we illustrate a 74-year-old patient presenting with clinical signs of slowly progressive motor neuron disease. After electromyography demonstrated myopathic changes, a skeletal muscle biopsy was performed showing histological signs of granulomatous myositis. In extensive diagnostic workup underlying primary granulomas forming diseases were excluded and corticoid therapy was initiated, but without clinical effect. We want to point out that granulomatous myositis should be considered in the differential diagnosis of slowly progressive motor neuron diseases, especially in atypical clinical presentations.

Key words: granulomatous myositis, motorneuron disease, sarcoidosis, granuloma

TO THE EDITOR

We describe a 74-year-old woman who presented with slowly progressive dysphagia, dysarthria and slight paresis of the right upper and left lower extremity for 5 years. Furthermore, painful muscle cramps and ubiquitous fasciculations were reported. Personal history revealed laryngeal cystectomy 4 years before after retention cysts were initially assumed to cause the dysphagia. Due to the clinical disease course, a slowly progressive motor neuron disease with isolated lower motor neuron affection was suspected. Neurological examination demonstrated mild bulbar paralysis and predominantly distal asymmetric muscular tetraparesis. Furthermore, ubiquitous fasciculations were observed. There were no clinical pyramidal tract signs. Cerebral and cervical magnetic resonance imaging remain unremarkable. Serum creatine-kinase was slightly increased (233 U/l; Norm < 110 U/l). Electrophysiologically, sensory and motor nerve conduction velocities as well as somatosensory and motor evoked potentials showed no abnormalities. Electromyography demonstrated ubiquitous fasciculations and exclusively myopathic changes predominantly in distal muscles of all extremities. Muscle magnetic resonance imaging of the lower extremities revealed oedema-like changes and fatty degeneration characterized by hyperintense signals in STIR and T2 weighted sequences (Fig.1a and b). Within the further diagnostics, a skeletal muscle biopsy from the left vastus lateralis muscle was performed. Routine histological stainings (including hematoxylin-eosine, Gomori's trichrome, NAD-H, peroxidase, cytochrome-c-oxidase, succinate-dehydrogenase, ATPase,

oil-red-o, and acid-phosphatase) revealed granulomatous myositis (Fig. 1c and d). There were no neurogenic changes, furthermore neither rimmed-vacuoles indicating inclusion-body-myositis nor histological signs of mitochondrial dysfunctions or glycogen storage disease. Within the further diagnostics, a sarcoidosis could be excluded by thoracic x-ray, angiotensin-converting enzyme blood testing, and FDG-PET. Furthermore, potentially granulomas forming infectious diseases were ruled out by extensive serum antibody testing. There was no evidence for malignancy. After exclusion of underlying primary disorders, an isolated granulomatous myositis was diagnosed and oral prednisolone therapy (initially 80 mg/day) was initiated, but without clinical obvious effect after 6 month of treating.

Granulomatous myositis is a rare condition with a prevalence of approximately 0.5% on skeletal muscle biopsy on large anatomopathologic series [1]. The association with sarcoidosis [2] is well known, furthermore with several infectious diseases, inflammatory bowel diseases, foreign-body giant-cell reaction, malignancy (lymphoma), thymoma, and myasthenia gravis [3]. In absence of sarcoidosis or other underlying disorders, the diagnosis of isolated granulomatous myositis is considered, but only two studies have focused on the clinical difference between these two disease forms [3, 4]. In the study of Mozaffar et al., 4 of 10 patients with a sarcoidosis related form had more severe proximal muscle weakness, whereas distal involvement was more common in isolated forms. Seven of eight symptomatic patients developed dysphagia during to the disease course due to a bulbar muscle involvement. A treatment with corticoids led to an improvement only in sarcoidosis related forms, not in isolated granulomatous myositis [4]. Le Roux and colleagues reported detailed clinical data of symptomatic granulomatous myositis [3]. All patients with sarcoidosis had predominantly symmetrical proximal weakness of the lower extremities, only 3 developed upper limb or distal involvement. Three of five patients with isolated granulomatous myositis had predominantly distal muscle weakness, two patients presented with dysphagia. Corticoid therapy led to a prolonged improvement in only one patient. A patient with acute sarcoid myositis benefited from methotrexate, other immunosuppressants and etanercept were ineffective. After re-examination, they found sarcoidosis associated myopathy to be more frequently associated with severe disability and rarely improved after corticosteroid therapy, compared with isolated granulomatous myositis.

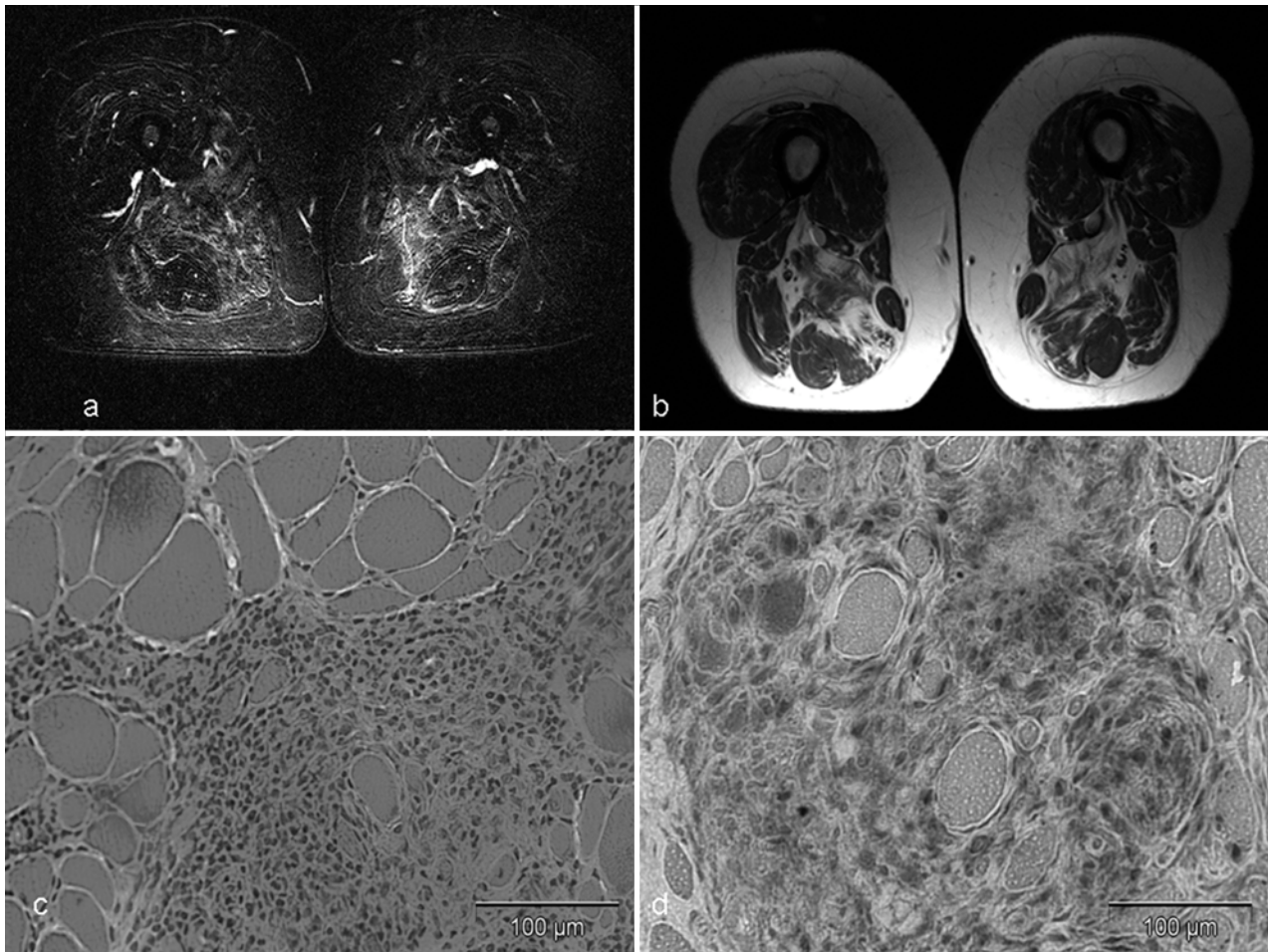


Fig. 1. Muscle MRI: Short tau inversion recovery (STIR) (a) and T2 (b) sequences demonstrating oedema-like changes and fatty degeneration. Muscle histology: Hematoxylin-eosine (c) and periodacid-schiff (d) staining showing endomyseal granulomas.

However, the main symptoms of our patient were dysarthria, dysphagia, and asymmetrical paresis. Consequently, initially a motor neuron disease was suspected. Atypical findings were the slowly progression of symptoms, the absence of clinical and electrophysiological signs of first motor neuron involvement, and the electromyographic verified myopathic pattern. Due to the fact, that differential diagnosis of slowly progressive lower motor neuron disease is extensive but also includes inflammatory myopathies, we want to point out that essentially in atypical disease presentations a skeletal muscle biopsy and facultative a muscle MRI should be performed to diagnose potentially treatable disorders, especially in cases with myopathic pattern in electromyographic examinations. Muscle magnetic resonance imaging may be a helpful tool in detecting muscle oedema or fatty degeneration suggesting myositis or myopathy, but can also guide a suitable place to biopsy. According to the data in the literature, isolated granulomatous myositis as well as sarcoidosis related granulomatous myositis should be treated with corticoids, although it seems to be impossible to predict the outcome in the individual case [3, 4]. In granulomatous myositis following infectious disease, malignancy, or other primary diseases the main focus should be on the treatment of the underlying disorder.

Acknowledgements: We thank Helga Mogel for preparing the stainings.

REFERENCES

1. Paryson RA. Granulomatous myositis. Clinicopathologic study of 12 cases. *Am J Clin Pathol* 1999;112:63-68.
2. Douglas AC, Macleod JG, Matthews JD. Symptomatic sarcoidosis of skeletal muscle. *J Neurol Neurosurg Psychiatry* 1973;36:1034-1040.
3. Le Roux K, Streichenberger N, Vial C, Petiot P, Feasson L, Bouhour F, Ninet J, Lachenal F, Broussolle C, Seve P. Granulomatous myositis: A clinical study of thirteen cases. *Muscle Nerve* 2007;35:171-177.
4. Mozaffar T, Lopate G, Pestronk A. Clinical correlates of granulomas in muscle. *J Neurol* 1998;245:519-524.

Received: July 2, 2007 / Accepted: January 24, 2008

Address for correspondence:

Hans-Jürgen Gdynia, M.D.
 Department of Neurology
 University of Ulm
 Oberer Eselsberg 45
 89081 Ulm, Germany
 Phone: +49-731/177-5225
 Fax: +49-731/177-1202
 E-mail: hans-juergen.gdynia@uni-ulm.de