

THREE-YEAR FOLLOW-UP OF A PATIENT WITH EARLY-ONSET ALZHEIMER'S DISEASE WITH PRESENILIN-2 N141I MUTATION CASE REPORT AND REVIEW OF THE LITERATURE

G. Nikisch¹, A. Hertel², B. Kießling¹, Th. Wagner¹, D. Krasz¹, E. Hofmann³, G. Wiedemann¹

¹Department of Psychiatry and Psychotherapy (Chief of Department: Prof. Dr. med. Georg Wiedemann),

²Department of Nuclear Medicine, (Chief of Department: Assistant Prof. Dr. med. Andreas Hertel),

³Department of Neuroradiology, (Chief of Department: Prof. Dr. med. Erich Hofmann),
Klinikum Fulda gAG, Fulda, Germany

Abstract

Autosomal dominant early-onset Alzheimer disease (EOAD) is a heterogeneous condition that has been associated with mutations in 3 different genes: the amyloid precursor protein (APP), presenilin 1 (PSEN1), and presenilin 2 (PSEN2) genes. Most cases are due to mutations in the PSEN1 gene, whereas mutations in the APP and PSEN2 genes are rare. Mutation analysis of the APP, PSEN1 and PSEN2 genes was performed. We herein report the case of a German EOAD patient with a family history of dementia and a missense mutation at codon 141 (N141I) of the PSEN2 gene. To our knowledge, this is the first German EOAD patient without a Volga-German ancestry and a positive family history for dementia carries the mutation PSEN-2 N141I. The patient came to our clinic for the first time when she was 47 years old. During the following 3 years, her Mini-Mental State Examination (MMSE) score dropped from 28 to 0. Mild cognitive impairment (MCI) was an early symptom that was already present during the first consultation. The concentration in cerebrospinal fluid (CSF) of tau-protein (1151 pg/ml) was increased, whereas the concentration of beta-amyloid protein (A β 1-42) was decreased (335 pg/ml). Magnetic resonance imaging (MRI) revealed only slight changes in the early stage of the disease and positron emission tomography with [18F] fluoro-2-deoxy-D-glucose (18F-FDG PET) demonstrated glucose reduction left parietal and in the precuneus region. Follow-up MRI and 18F-FDG PET studies showed progression of atrophy of the left entorhinal cortex with relative sparing of the hippocampus and progressive hypometabolism of both temporoparietal lobes and left frontal lobe.

Key words: MCI; early-onset Alzheimer disease; presenilin-2; N141I; MRI; 18F-FDG PET

INTRODUCTION

Alzheimer disease (AD) is characterized by memory loss and declining cognitive functions. Patients with an

early onset (onset < 65 years) demonstrate a faster progression and a more severe clinical presentation than those with a late onset (onset > 65 years), despite being younger. Autosomal dominant early-onset Alzheimer disease (EOAD) is a heterogeneous condition caused by different genetic defects. Familial studies, in early-onset cases, indicate molecular heterogeneity and have linked EOAD to mutations in at least three genes: the amyloid precursor protein gene (APP) located on chromosome 21 (Mullan and Crawford 1993) and the presenilin 1 and 2 (PSEN-1 and PSEN-2, respectively) genes located on chromosome 14 and 1 (Levy-Lahad et al. 1995; Sherrington et al. 1995), respectively. Mutations in these genes account for approximately half of the EOAD (Rosenberg 2000). Although more than 166 mutations in the PSEN1 gene have been associated with autosomal dominant EOAD, only 13 such mutations have been found in the PSEN2 gene (Finckh et al. 2005). Mutations in the PSEN2 gene on chromosome 1 are the second most frequent form of familial EOAD (age at onset 45-65 years) and have mainly been described in large kindreds of Volga-Germans in the U.S. (Levy-Lahad et al. 1995; Mann et al. 1997).

It has been reported that 10-15% of patients with mild cognitive impairment (MCI) develop Alzheimer's disease (AD) within 1 year (Peterson et al. 1999). Evidence shows that these pathological changes are detectable before the onset of clinical dementia (Morris and Price 2001). As clinically mildly demented AD patients show elevated tau-protein levels (Galasko 1998; Riemenschneider et al. 1996) and decreased A β 1-42 levels (Andreasen et al. 1999; Galasko 1998; Motter et al. 1995) in cerebrospinal fluid (CSF) compared to controls. CSF tau protein and A β 1-42 have been proposed as putative early diagnostic markers in MCI subjects. Patients who converted from MCI to AD showed significantly higher tau-protein levels at baseline compared to healthy individuals (Arai et al. 1997). Moreover, it has been demonstrated that subjects with MCI who later developed AD were identified by the combination of decreased CSF concentrations of A β 1-42 and increased levels of tau-protein (Andreasen

et al. 1999; Riemenschneider et al. 2002). These findings suggest that tau-protein and A β 1-42 in CSF may be valuable to detect the preclinical stages of AD.

Up to now only two cases of EOAD due to mutations in the PSEN2 gene have been identified in Germany (Finckh et al. 2005). We describe the clinical course of a patient with the N141I mutation of PSEN2.

CASE REPORT

The patient was admitted to our psychiatric clinic for the first time at the age of 48 years. From the age of 47 years she had started to complain about deficits in her short-term memory. There was no previous history of severe or chronic illnesses. The patient had no evidence or history of neurological signs or symptoms of cerebrovascular disease. Her orientation in person, situation and time were adequate. She was unable to date biographical events of the few years and she was aware of her cognitive deficits. Physical examination and laboratory test was normal (including Vitamin B12, TSH, and TPHA). The patient had completed secondary school and education as an industrial clerk. She married at the age of 18, and gave birth to one son.

The family history revealed that the father (II-2) and the grandmother (I-1) of the index patient suffered from AD (Fig. 1A). The grandmother died at age 52 years after a clinical course of approximately 5 years on the sequelae of pneumonia with an onset at 48 years. The index patient's father showed first mild cognitive impairments at age of 64 years and died at age 76 years. The 77-year old mother (II-1) of the index patient, and her three siblings aged 52, 50 and 46 (III-1, 3, 4, respectively) are asymptomatic at the time of clinical examination and genetic data were not collected. The healthy son (IV-1) of the index patient reported here has a 50% chance of being a carrier of the N141I mutation. Predictive testing was not performed.

METHODS AND RESULTS

NEUROPSYCHOLOGICAL EXAMINATION

The Mini-Mental-State-Examination (MMSE), the Hamburg-Wechsler-Intelligence Test for Adults (HAWIE) and the Hamilton Depression Scale (HAM-D) were used to determine the patient's cognitive abilities. At the first presentation the patient reached a score of 28 points on the MMSE. The HAWIE showed a total IQ of 93 with a relevant discrepancy between the verbal IQ of 101 and the performance IQ of 84. This is mainly due to the inability of the patient to distinguish between important and less important information of the serial picture stories used in these IQ subtests. The HAM-D showed a mildly elevated for depression.

ELECTROPHYSIOLOGICAL TESTS

At the first presentation the electroencephalogram (EEG) at the age of 48 years showed a slow alpha rhythm (6/s) with paroxysmal activation of irregular

frontotemporal theta wave activity. The EEG at the age of 51 years showed delta-theta wave activity with paroxysmal activation of frontal sharp and slow waves.

CEREBROSPINAL FLUID (CSF)

The analysis of CSF revealed normal cell count and protein content. There were no oligoclonal bands. NSE and protein 14-3-3 were within the normal range. Tau-protein was elevated 1151 pg/ml (normal range: 47-225 pg/ml) and A β 1-42 decreased 335 pg/ml (normal range: 576-1012 pg/ml).

BRAIN IMAGING DATA: MRI AND 18F-FDG PET

Our patient received a standardized clinical MRI scan protocol with T1- weighted and T2- weighted sequences to visualize structural brain changes as volume reductions (i.e., atrophy). A PET scan, which images regional brain metabolism with the use of 18F-FDG, was obtained. At the first presentation MRI scanning showed slightly changes at the age of 48 and 18F-FDG PET images already showed reduction of cortical glucose metabolism in the left parietal and precuneus cortex (Fig. 2A). Follow-up MRI and 18F-FDG PET studies showed progression of atrophy of the left entorhinal cortex with relative sparing of the hippocampus and progressive hypometabolism of bilaterally temporoparietal lobes with additional frontal hypometabolism more apparent on the left lobe three years later (Fig. 2B).

GENETIC DIAGNOSIS

After gaining written informed consent, a blood sample for genetic analysis was obtained from the proband. The DNA was isolated according to standard procedures. The coding regions of the PSEN1, PSEN2, and APP (exons 2, 16 and 17) were amplified using specific primers, as described previously (Cruts et al. 1998; Mullan et al.) A heterozygote missense mutation resulting in a substitution of asparagine at position 141 by isoleucine (N141I) in exon 5 of PSEN2 was detected (Fig. 2B).

FOLLOW-UP AND COURSE OF THE DISEASE

The patient showed progressive mental decline. Neuropsychological assessment, approximately 2 years after disease onset, shows marked intellectual loss. All measures of auditory and visual memory for immediate and delayed recall were severely impaired (below the first percentile). Acetylcholinesterase inhibitor and a NMDA receptor antagonist were prescribed (donepezil, followed by memantine) but were not beneficial; one year after presentation MMSE had dropped to 14 and to 0 two years later. The neuropsychological profile was consistent with AD. When the patient was 50 years old she was no longer able to take care of herself. She became dependent with activities such as shopping and housekeeping. At the age of 51 years, the patient was unable to repeat words or to follow instructions. She spoke only single words which were remotely connected to the actual situation.

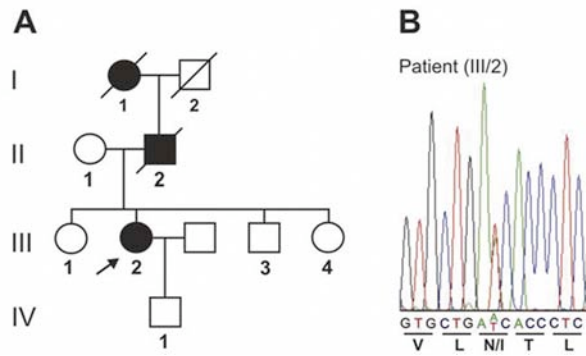


Fig. 1. (A): Pedigree of the German FAD family carrying the N141I mutation in PSEN2. Black symbols indicate affected probands. The index patient is marked by an arrow. (B): DNA sequence chromatogram of part of PSEN2 exon 5, showing the heterozygous A to T transversion in the index patient (III-2). Corresponding reading frame and amino acid sequence is given.

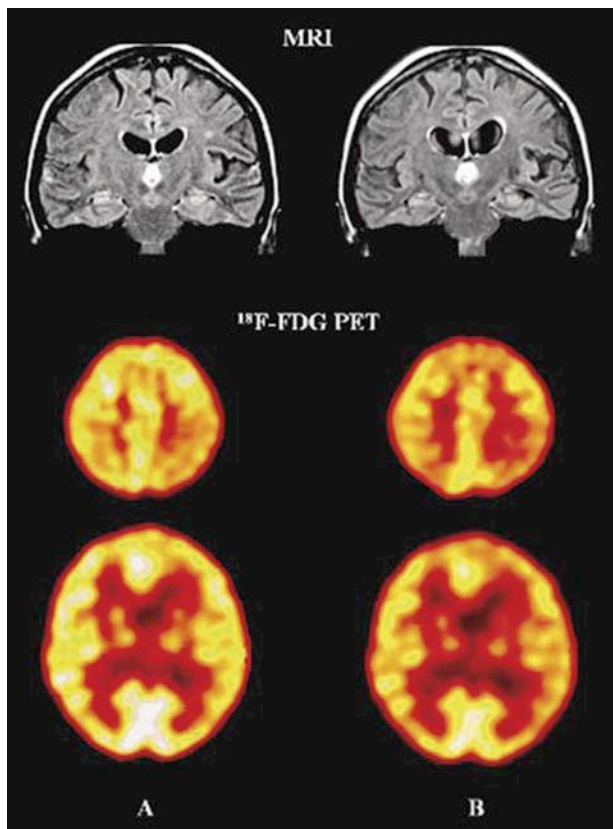


Fig. 2. MRI scans shown atrophy of the left entorhinal cortex with relative sparing of the hippocampus. 18F-FDG PET scans showing progressive hypometabolism of both temporoparietal lobes and left frontal lobe between May 2005, already beginning in the left parietal cortex (A) and February 2008 (B).

DISCUSSION

Herein we document clinical and operative findings in a German patient with early-onset Alzheimer dementia (EOAD) and with a mutation at codon 141 in the PSEN-2 gene. The same mutation has been shown

to cosegregate in an autosomal dominant way with EOAD in Volga-Germans in the U.S. (Levy-Lahad et al. 1995; Mann et al. 1997).

This case is unique in many respects. Although the symptoms, signs, investigations, progress, and family history are consistent with familial EOAD, the neuropsychological follow-up changes of her affected relatives – who shared a similar presentation – showed the changes seen most often in MCI (Peterson et al. 1999). Cognitive deficits became obvious when she was 47 years old with an onset of dementia in her family at 48 years and 64 years. MCI was an early symptom that was already present during the first consultation. Our patient's genetic analysis showed a heterozygote missense mutation resulting in a substitution of asparagine at position 141 by isoleucine in exon 5 of PSEN2 sequence.

Although we were not able to analyse the PSEN-2 gene in the other two affected relatives, the detected PSEN-2 mutation strongly suggests a genetic origin of EOAD in the other members of this family.

Linkage of PSEN-2 mutations with the autosomal transmission of familial EOAD has been shown for 13 different positions in the PSEN-2 gene (Table 1). Estimations of the frequency of occurrence of mutations in the PSEN-2 gene in pedigrees with suspected familial EOAD vary between 3-5%. Whether there are significant differences in clinical symptomatology be-

Table 1. Known mutations of the PSEN-2 gene on chromosome 1 associated with early-onset Alzheimer's disease (EOAD). <http://www.molgen.ua.ac.be/ADMutations/>

No.	Mutation	Exon / Domain	Author / Year
1	Arg 62 His (g.1839 G>A)	4 / N -Term	Cruts et al. 1998
2	Ala 85 Val (g.1908 C>T)	4 / N -Term	Piscopo et al. 2005
3	Thr 122 Pro (g. 3636 A>C)	5 / HL - I	Finckh et al. 2000 Finckh et al. 2005
4	Thr 122 Arg (g.3637 C>G)	5 / HL - I	Binetti et al. 2003
5	Ser 130 Leu (g. 3661C>T)	5 / HL - I	Sorbi et al. 2002 Tedde et al. 2003 Tomaino et al. 2007
6	Asn 141 Ile (g. 3694 A>T)	5 / TM - II	Levy-Lahad et al. 1995 Rogaev et al. 1995
7	Val 148 Ile (g. 3714 G>A)	5 / TM - II	Beyer et al. 1998 Lao et al. 1998
8	Gln 228 Leu (g. 7039 A>T)	7 / TM - V	Zekanowski et al. 2003
9	Met 239 Val (g. 7071 A>G)	7 / TM - V	Rogaev et al. 1995
10	Met 239 Ile (g. 7073 G>A)	7 / TM - V	Finckh et al. 2000 Finckh et al. 2000
11	Pro 334 Arg (g. 9867 C>G)	10 / HL - VI b	Lleo et al. 2002 Lleo et al. 2002
12	Thr 430 Met (g. 13615 C>T)	12 / TM - IX	Lleo et al. 2002 Ezquerria et al. 2003
13	Asp439Ala (g. 13642 A>C)	12 / C - Term	Lleo et al. 2001 Lleo et al. 2002

tween different mutations of the PSEN-2 gene awaits further investigation. Some of these families show a wide range in age at onset, and cases of nonpenetrance have been found (Cruets et al. 1998; Finckh et al. 2005; Levy-Lahad et al. 1995; Tomaino et al. 2007).

In our family, there was an almost 15-year gap between the proband and parent in age at disease onset. Although a longer follow-up period is needed, the presence of a cognitively healthy mutation carrier could indicate the existence of incomplete penetrance. Nevertheless, we can not rule out that this individual is at risk for EOAD. The variation in age at onset observed in this family confirms that PSEN2 mutations are associated with variable clinical expression. This fact has important consequences for genetic-testing and genetic-counseling programs; it may determine the type of information given to these families.

The N141I mutation is located in exon 5 of the PSEN2 gene, near the D439A mutation and the C-terminal end of the protein. The presenilin 2 protein is an integral transmembrane protein normally processed by proteolytic cleavage. Interestingly, the C-terminus is a critical region for endoproteolytic processing and possibly for the pathologic function of the protein (Shirontani et al. 2000). Thus; the N141I mutation could disrupt the endoproteolytic process and interfere with the normal function of the protein.

The diagnosis of primary degenerative dementia disorders such as AD is made largely by excluding other causes of dementia. The search for biochemical diagnostic markers that could be used for an early diagnosis of AD has led to the suggestion that the concentrations of tau-protein and the 42-amino acid form of A β 1-42 in cerebrospinal fluid (CSF) have a diagnostic value (Andreasen et al. 2001; Hulstaert et al. 1999).

Tau-protein is a normal axonal protein, which by binding to tubulin in microtubules promotes their assembly and stability (Goedert 1993). An increase in CSF-tau-protein in AD has been found in numerous studies (Arai et al. 1997; Blennow et al. 1995; Jensen et al. 1995; Vandermeeren et al. 1993), which probably reflects the neuronal and axonal degeneration (Blennow et al. 1995; Vanmechelen et al. 1996), or possibly the successive accumulation of neurofibrillary tangles in AD (Tapiola et al. 1997). The sensitivity of CSF-tau-protein for AD in several studies has been high, often 80-90% (Andreasen et al. 1998, Andreasen et al. 1999; Galasko 1998). The specificity has also been relatively high because most patients with other dementias, chronic neurologic disorders (e.g., Parkinson disease), or psychiatric diagnoses (e.g., depressive pseudo-dementia) have physiologic CSF tau-protein values (Blennow et al. 1995; Mecocci et al. 1998; Sjögren et al. 2000).

A β 1-42 has been implicated in the pathogenesis of AD and is the core peptide that accumulates in senile plaques (Tamaoka et al. 1995). Several studies have found that CSF- A β 1-42 is decreased in AD (Andreasen et al. 1999; Galasko et al. 1997; Motter et al. 1995; Sjögren et al. 2000). A high sensitivity (80-90%) for CSF- A β 1-42 as a marker for AD has been found (Andreasen et al. 1999; Galasko 1998), whereas the specificity has to be investigated further. Concomitant

measurements of CSF-tau and CSF-A β 1-42 have been suggested to increase the diagnostic precision of AD (Galasko 1998; Hulstaert et al. 1999). As part of the clinical routine, these markers have been found to be highly sensitive and specific (Andreasen et al. 1998; Andreasen et al. 2001).

Hampel et al. (2004) studied 52 patients with MCI, 93 AD patients, and 10 healthy controls (HC). The MCI group was composed of 29 patients who had converted to AD during follow-up, and of 23 patients who showed no cognitive decline. The levels of CSF tau-protein were increased, whereas levels of A β 1-42 were decreased in MCI subjects. A β 1-42 predicted AD in converted MCI with a sensitivity of 59% and a specificity of 100% compared to HC. Tau-protein yielded a greater sensitivity of 83% and a specificity of 90%.

Regarding its potential role in AD, studies with transfected cell lines and transgenic animals expressing mutant PSEN-2 showed an alteration in amyloid processing leading to a higher production of A β 1-42 /1-43 (Citron et al. 1997; Tomita et al. 1997).

The present MRI and 18F-FDG PET studies demonstrated that the missense mutation at codon 141 of the PSEN2 gene, the MCI present during the first consultation and the elevated tau-protein levels and decreased A β 1-42 levels in CSF interact in their effect on brain metabolism in specific brain areas. Our findings are interesting as several 18F-FDG PET studies have been published predicting the decline from normal to MCI. This studies showed that reduced baseline metabolic levels in the entorhinal cortex, which is part of the medial temporal lobes (MTL, i.e., hippocampus, transentorhinal and entorhinal cortices, and parahippocampal gyrus), predict an MCI diagnosis 3 years later (de Leon et al. 2001; Gary et al. 2000). The baseline metabolic reduction predicted decline to MCI with 83% sensitivity and 85% specificity. No cortical regions showed preclinical effects. Moreover, progressive metabolic reductions in the entorhinal cortex and in the left lateral temporal lobe paralleled the onset of MCI, which is of interest, as an ideal biomarker for EOAD must correlate with disease progression.

CONCLUSIONS

Although mutations in the genes for PSEN-1, PSEN-2 and APP cause familial EOAD, it must be remembered that the majority of EOAD is not genetically determined but belongs to the sporadic type of AD. EOAD due to a mutation in the PSEN-2 gene seems to be rare in Germany. Our findings support the notion that CSF tau-protein, A β 1-42 and structural and functional neuroimaging (MRI, 18F-FDG PET) may be useful biomarkers in the early identification of AD in MCI subjects.

Acknowledgements: We thanks Ulrich Müller and Dagmar Nolte (Institute of Human Genetics at the University of Gießen/Marburg, Germany) for the critical, stimulating and motivating comments on the final version of the article.

REFERENCES

- Andreasen N, Hesse C, Davidsson P, Minthon L, Wallin A, Winblad B. Cerebrospinal fluid beta-amyloid (1-42) in Alzheimer disease: differences between early- and late-onset Alzheimer disease and stability during the course of disease. *Arch Neurol* 1999;56:673-80.
- Andreasen N, Minthon L, Davidsson P, Vanmechelen E, Vanderstichele H, Winblad B, Blennow K. Evaluation of CSF-tau and CSF-A β 42 as diagnostic markers for Alzheimer's disease in clinical practice. *Arch Neurol* 2001;58:373-9.
- Andreasen N, Vanmechelen E, Van de Voorde A, Davidsson P, Hesse C, Tarvonen S. Cerebrospinal fluid tau protein as a biochemical marker for Alzheimer's disease: a community based follow up study. *J Neurol Neurosurg Psychiatry* 1998;64:298-305.
- Arai H, Nakagawa T, Kosaka Y, Higuchi M, Matsui T, Okamura N. Elevated cerebrospinal fluid tau protein level as a predictor of dementia in memory-impaired individuals. *Alzheim Res* 1997;3:211-3.
- Arai H, Terajima M, Miura M, Higuchi S, Muramatsu T, Machida N. Tau in cerebrospinal fluid: a potential diagnostic marker in Alzheimer's disease. *Ann Neurol* 1995;38:649-52.
- Beyer K, Lao JI, Fernandandez-Novoa L, Cacabelos R. Identification of a novel mutation (V148I) in the TM2 domain of the presenilin 2 gene in a patient with late-onset Alzheimer disease. *Neurobiology of Aging* 1998;19:87-8.
- Binetti G, Signorini S, Squitti R, Alberici A, Benussi L, Cassetta E, Frisoni GB, Barbiero L, Feudatari E, Nicosia F, Testa C, Zanetti O, Gennarelli M, Perani D, Anchisi D, Ghidoni R, Rossini PM. Atypical dementia associated with a novel presenilin-2 mutation. *Annals of Neurology* 2003;54:832-6.
- Blennow K, Wallin A, Agren H, Spenger C, Siegfried J, Vanmechelen E. Tau protein in cerebrospinal fluid: a biochemical marker for axonal degeneration in Alzheimer disease? *Mol Chem Neuropathol* 1995;26:231-45.
- Citron M, Westaway D, Xia WM, Carlson G, Diehl T, Levesque G, Johnson-Wood K, Lee M, Seubert P, Davis A, Kholodenko D, Motter R, Sherrington R, Perry B, Yao H, Strome R, Lieberburg I, Rommens J, Kim S, Schenk D, Fraser P, Hyslop PS, Selkoe DJ. Mutant presenilins of Alzheimer's disease increase production of 42-residue amyloid β -protein in both transfected cells and transgenic mice. *Nature Med* 1997;3:67-72.
- Cruts M, van Duijn CM, Backhovens H, Van den Broeck M, Wehnert A, Serneels S, Sherrington R, Hutton M, Hardy J, St George-Hyslop PH, Hofman A, Van Broeckhoven C. Estimation of the genetic contribution of presenilin-1 and -2 mutations in a population-based study of presenile Alzheimer disease. *Human Molecular Genetics* 1998;7:43-51.
- de Leon MJ, Convit A, Wolf OT. Prediction of cognitive decline in normal elderly subjects with 2-[18F]fluoro-2-deoxy-Dglucose/positron-emission tomography (FDG/PET). *Proc Natl Acad Sci* 2001;98:10966-71.
- Ezquerra M, Lleo A, Castellvi M, Queralt R, Santacruz P, Pastor P, Molinuevo JL, Blesa R, Oliva R. A novel mutation in the PSEN2 gene (T430M) associated with variable expression in a family with early-onset Alzheimer disease. *Archives of Neurology* 2003;60:1149-51.
- Finckh U, Kuschel C, Anagnostouli M, Patsouris E, Pantos GV, Gatzonis S, Kapaki E, Davaki P, Lamszus K, Stavrou D, Gal A. Novel mutations and repeated findings of mutations in familial Alzheimer disease. *Neurogenetics* 2005;6:85-9.
- Finckh U, Muller-Thomsen T, Mann U, Eggers C, Marksteiner J, Meins W, Binetti G, Alberici A, Hock C, Nitsch RM, Gal A. High Prevalence of Pathogenic Mutations in Patients with Early-Onset Dementia Detected by Sequence Analyses of Four Different Genes. *American Journal of Human Genetics* 2000;66:110-7.
- Galasko D. CSF tau and A β 42: logical biomarkers for Alzheimer's disease? *Neurobiol Aging* 1998;19:117-9.
- Galasko D, Clark C, Chang L, Miller B, Green RC, Rotter R. Assessment of CSF levels of tau protein in mildly demented patients with Alzheimer's disease. *Neurology* 1997;48:632-5.
- Gary W, Small L, Ercoli D. Cerebral metabolic and cognitive decline in persons at genetic risk for Alzheimer's disease. *Proc Natl Acad Sci* 2000;97:6037-42.
- Goedert M. Tau protein and the neurofibrillary pathology of Alzheimer's disease. *Trends Neurosci* 1993;16:460-5.
- Hampel H, Teipel SJ, Fuchsberger T, Andreasen N, Wiltfang J, Otto M, Shen Y, Dodel R, Du Y, Farlow M, Moller H-J, Blennow K, Buerger K. Value of CSF β -amyloid 1-42 and tau as predictors of Alzheimer's disease in patients with mild cognitive impairment. *Molecular Psychiatry* 2004;9:705-10.
- Hulstaert F, Blennow K, Ivanoiu A, Schoonderwaldt HC, Riemenschneider M, De Deyn PP. Improved discrimination of AD patients using β -amyloid (1-42) and tau levels in CSF. *Neurology* 1999;52: 1555-62.
- Jensen M, Basun H, Lannfelt L. Increased cerebrospinal fluid tau in patients with Alzheimer's disease. *Neurosci Lett* 1995;186:189-91.
- Lao JI, Beyer K, Novoa LF, Cacabelos R. A novel mutation in the predicted TM2 domain of the presenilin 2 gene in a Spanish patient with late-onset disease. *Neurogenetics* 1998;1:293-6.
- Levy-Lahad E, Wasco W, Poorkaj P, Romano DM, Oshima J, Pettingell WH, Yu CE, Jondro PD, Schmidt SD, Wang K, Crowley AC, Fu Y-H, Guenette SY, Galas D, Nemens E, Wijsman EM, Bird TD, Schellenberg GD, Tanzi RE. Candidate gene for the chromosome 1 familial Alzheimer's disease locus. *Science* 1995;269:973-7.
- Lleo A, Blesa R, Gendre J, Castellvi M, Pastor P, Queralt R, Oliva R. A novel presenilin 2 gene mutation (D439A) in a patient with early-onset Alzheimer's disease. *Neurology* 2001;57:1926-8.
- Lleo A, Blesa R, Queralt R, Ezquerra M, Molinuevo JL, Penas-Casanova J, Rojo A, Oliva R. Frequency of mutations in the presenilin and amyloid precursor protein genes in early-onset Alzheimer disease in Spain. *Archives of Neurology* 2002;59:1759-63.
- Mann DMA, Iwatsubo T, Nochlin D, Sumi SM, Levy-Lahad E, Bird TD. Amyloid (A β) deposition in chromosome 1-linked Alzheimer's disease: the Volga German families. *Ann Neurol* 1997;41:52-7.
- Mecocci P, Cherubini A, Bregnocchi M, Chionne F, Cecchetti R, Lowenthal DT. Tau protein in cerebrospinal fluid: a new diagnostic and prognostic marker in Alzheimer disease? *Alzheimer Dis Assoc Disord* 1998;12:211-4.
- Morris JC, Price AL. Pathologic correlates of nondemented aging, mild cognitive impairment, and early-stage Alzheimer's disease. *J Mol Neurosci* 2001;17:101-18.
- Motter R, Vigo Pelfrey C, Kholodenko D, Granerus A-K, Clarberg A, Vanderstichele H. Reduction of β -amyloid peptide 42 in the cerebrospinal fluid of patients with Alzheimer's disease. *Ann Neurol* 1995;38:643-8.
- Mullan M, Crawford F. Genetic and molecular advances in Alzheimer's disease. *Trends Neurosci* 1993;16:398-403.
- Petersen RC, Smith GE, Waring SC, Ivnik RJ, Tangalos EG, Kokmen E. Mild cognitive impairment: clinical characterization and outcome. *Arch Neurol* 1999;56:303-8.
- Piscopo P, Crestini A, Malvezzi-Campeggi L, Manfredi A, Deiana E, Cherchi R, Vanacore N, Marcon G, Piras MR, Confaloni AM. A novel PSEN-2 mutation in a large Italian pedigree. *Alzheimer's and Parkinson's Diseases: In-*

- sights, Progress and Perspectives. 7th International Conference AD/PD Book of Abstracts 2005;24.
- Riemenschneider M, Buch K, Schmolke M, Kurz A, Guder WG. Cerebrospinal protein tau is elevated in early Alzheimer's disease. *Neurosci Lett* 1996;212:209-11.
- Riemenschneider M, Lautenschlager N, Wagenpfeil S, Diehl J, Drzezga A, Kurz A. Cerebrospinal fluid tau and beta-amyloid 42 proteins identify Alzheimer disease in subjects with mild cognitive impairment. *Arch Neurol* 2002;59:1729-34.
- Rogaev EI, Sherrington R, Rogaeva EA, Levesque G, Ikeda M, Liang Y, Chi H, Lin C, Holman K, Tsuda T, Mar L, Sorbi S, Nacmias B, Piacentini S, Amaducci L, Chumakov I, Cohen D, Lannfelt L, Fraser PE, Rommens JM, St George-Hyslop PH. Familial Alzheimer's disease in kindreds with missense mutations in a gene on chromosome 1 related to the Alzheimer's disease type 3 gene. *Nature* 1995;376:775-8.
- Rosenberg RN. The molecular and genetic basis of AD: the end of the beginning. *Neurology* 2000;54:2045-54.
- Sherrington R, Rogaev EI, Liang Y. Cloning of a gene bearing missense mutations in early-onset familial Alzheimer's disease. *Nature* 1995;375:754-60.
- Shirotani K, Takahashi K, Araki W. Mutational analysis of intrinsic regions of presenilin 2 that determine its endoproteolytic cleavage and pathological function. *J Biol Chem* 2000;275:3681-6.
- Sjögren M, Minthon L, Davidsson P, Granerud A-K, Clarberg A, Vanderstichele H. CSF levels of tau, β -amyloid 42 and GAP-43 in frontotemporal dementia, other types of dementia and normal aging. *J Neural Transm* 2000;105:563-79.
- Sorbi S, Tedde A, Nacmias B, Ciantelli M, Caffarra P, Ghidoni E, Bracco L, Piccini C. Novel presenilin 1 and presenilin 2 mutations in early-onset Alzheimer's disease families. *Neurobiology of Aging* 2002;23:312-3.
- Tamaoka A, Sawamura N, Odaka A, Suzuki N, Mizusawa H, Shoji S. Amyloid β protein 1-42/43 (A β 1-42/43) in cerebellar diffuse plaques: enzyme-linked immunosorbent assay and immunocytochemical study. *Brain Res* 1995;679:151-6.
- Tapiola T, Overmyer M, Lehtovirta M, Helisalmi S, Ramberg J, Alafuzoff I. The level of cerebrospinal fluid tau correlates with neurofibrillary tangles in Alzheimer's disease. *Neuroreport* 1997;8:3961-3.
- Tedde A, Nacmias B, Ciantelli M, Forleo P, Cellini E, Bagnoli S, Piccini C, Caffarra P, Ghidoni E, Paganini M, Bracco L, Sorbi S. Identification of new presenilin gene mutations in early-onset familial Alzheimer disease. *Archives of Neurology* 2003;60:1541-4.
- Tomaino C, Bernardi L, Anfossi M, Costanzo A, Ferrise F, Gallo M, Geracitano S, Maletta R, Curcio SA, Mirabelli M, Colao R, Frangipane F, Puccio G, Calignano C, Muraica MG, Paonessa A, Smirne N, Leotta A, Bruni AC. Presenilin 2 Ser130Leu mutation in a case of late-onset "sporadic" Alzheimer's disease. *Journal of Neurology* 2007;254:391-3.
- Tomita T, Maruyama K, Saido TC, Kume H, Shinozaki K, Tokunishi S, Capell A, Walter J, Grunberg J, Haass C, Iwatsubo T, Obata K. The presenilin 2 mutation (N141I) linked to familial Alzheimer's disease (Volga German families) increases the secretion of amyloid beta ending at the 42nd (or 43rd) residue. *Proc Natl Acad Sci USA* 1997;94:2095-7.
- Vandermeeren M, Mercken M, Vanmechelen E, Six J, van de Voorde A, Martin JJ, Cras P. Detection of tau proteins in normal and Alzheimer's disease cerebrospinal fluid with a sensitive sandwich enzyme-linked immunosorbent assay. *J Neurochem* 1993;61:1828-34.
- Vanmechelen E, Blennow K, Davidsson P, Cras P, Van de Voorde A. Combination of tau/phospho-tau with other biochemical markers for Alzheimer CSF diagnosis and tau in CSF as marker for neurodegeneration. In: Iqbal K, Winblad B, Nishimura T, Takeda M, Wisniewski HM (eds) *Alzheimer's disease: biology, diagnosis and therapeutics*. Wiley, Chichester, pp. 1996;197-203.
- Zekanowski C, Styczynska M, Peplonska B, Gabryelewicz T, Religa D, Ilkowski J, Kijanowska-Haladyna B, Kotapka-Minc S, Mikkelsen S, Pfeffer A, Barczak A, Luczywek E, Wasiak B, Chodakowska-Zebrowska M, Gustaw K, Laczkowski J, Sobow T, Kuznicki J, Barcikowska M. Mutations in presenilin 1, presenilin 2 and amyloid precursor protein genes in patients with early-onset Alzheimer's disease in Poland. *Experimental Neurology* 2003;184:991-6.

Received: June 4, 2008 / Accepted: July 21, 2008

Address for correspondence:

Dr. med. Dipl.-Psych. G. Nikisch
 Department of Psychiatry and Psychotherapy
 Klinikum Fulda gAG
 Pacelliallee 4
 36043 Fulda
 Germany
 Phone: +49 661 84 5736
 Fax: +49 661 84 5722
 E-mail: georg.nikisch@klinikum-fulda.de