

Images in Medical Research

HYBRID RENDERING OF AORTIC ANEURYSMS AFTER ENDOLUMINAL STENT-GRAFT REPAIR

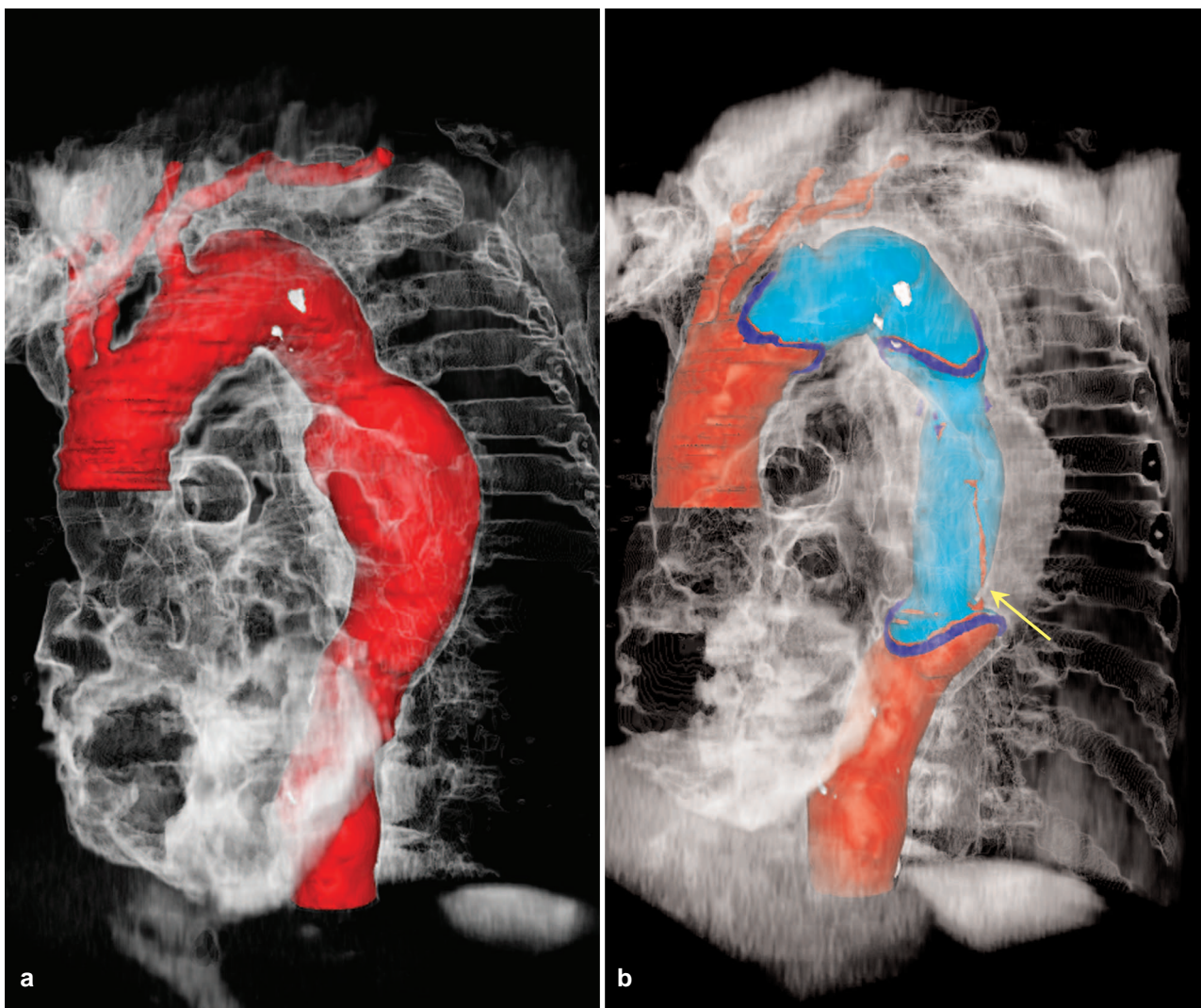
M. D. Seemann^{1,3}, F. Schmid^{2,3}, K.-H. Englmeier³¹Department of Nuclear Medicine, Technical University, Munich, Germany²Department for Radiological Diagnostics, Ulm University Hospital, Germany³Institute of Medical Informatics, GSF - Research Centre for Environment and Health, Neuherberg, Germany

Fig. 1. A 63-year-old female patient with a descending thoracic aortic aneurysm. (a) Left anterior oblique view, showing a hybrid rendering of the thorax with a color-coded shaded-surface rendered model of the thoracic aorta (red) and a volume rendered model of the other thoracic structures (transparent, white). (b) Left anterior oblique view after endoluminal placement of two stent-grafts, showing a hybrid rendering of the thorax with a color-coded shaded-surface rendered model of the thoracic aorta (red), the stent-grafts (light blue), the terminal metallic markers of the stent-graft (dark blue) and an endoleak arises from a defect in the graft fabric (Type III) (red, arrow) and a volume rendered model of the other thoracic structures (transparent, white), inclusive of the excluded descending thoracic aortic aneurysm. The stent-grafts used to treat the aneurysm were composed of woven polyester graft material with a ring of stainless steel at the ends.

The endoluminal repair of aortic aneurysms with stents or stent-graft prostheses is an important alternative to surgical repair. Spiral computed tomographic angiography has been used to control the success of endoluminal repair with increasing frequency as an alternative to the more invasive conventional angiography. With the increasing use of multi-detector row spiral CT (MDCT) scanners, image processing methods will gain more and more importance for the presentation of anatomical and pathological findings.

The hybrid rendering method is a promising 3D visualization technique which combines a color-coded surface rendering method and a volume rendering method. To produce and process such an innovative rendering technique, we used a high performance graphic computer and an in-house developed software package. The aorta and the stent-grafts were identified using an interactive, automatic threshold interval, density volume-growing segmentation process and visualized with a color-coded shaded-surface rendering method. The volume rendering method provides, by varying the degree of transparency, the image information of the surrounding bone and soft tissue structures, through a direct 3D visualization of the complete volume data set.

The hybrid rendering technique exploit the advantages of both rendering methods, provides an excellent overview of the vascular system, enables a clear and

detailed representation and assessment of the spatial relationships of anatomical and pathological features and provide the diagnostic information without the need for time consuming detailed analysis and presentation of axial source images. Therefore, during hybrid rendering there is no loss of image information as occurs in a purely color-coded surface rendering method, rather the image information is given a weighting related to the importance of interest in the previously defined structures. The hybrid 3D models could be varied in size and rotated in real time to facilitate a detailed assessment of each structure and allow measurements of distance and volume in any planes, for example the measurements of the extension of endoleaks.

Received: March 14, 2005 / Accepted: April 13, 2005

Address for correspondence:

Marcus D. Seemann, M.D.
Associate Professor of Radiology
Department of Nuclear Medicine
Technical University, Munich
Ismaninger Str. 22
D-81675 Munich, Germany
Tel.: ++49-89/4140 2971
Fax: ++49-89/4140 4841
e-mail: m.seemann@lrz.tum.de