

BILATERAL INTERNAL CAROTID ARTERY DISSECTIONS RELATED TO PREGNANCY AND CHILDBIRTH

H.-J. Gdynia, R. Huber

University of Ulm, Department of Neurology, Ulm, Germany

Abstract

We illustrate a 35 years old woman presenting with acute left hemiplegia three weeks after caesarean section. Cerebral MRI demonstrated acute right frontoparietal ischemic stroke, while angiographic investigations provided acute occlusion of the proximal right internal carotid artery due to a dissection and two additional dissections of the proximal and distal contralateral internal carotid artery. A skin biopsy revealed alterations like in some types of Ehlers-Danlos syndrome. Pregnancy, caesarean section, and possibly hormonal implicated connective tissue changes may have contributed to the dissections. Remarkably a second pregnancy with a close ultrasonographic vascular monitoring two years later succeeded upon caesarean section without complications, which gives an important input in the gestational guidance of risk patients.

Key words: Dissection, pregnancy, caesarean section, connective tissue

CASE REPORT

A 35 years old woman presented with acute left facial palsy and sensorimotor paresis of the upper left extremity. There were no further accompanying symptoms, neither headache nor neck pain. Cerebral MRI demonstrated acute right frontoparietal cortical ischemic stroke. Personal history revealed an uncompl-

icated caesarean section after strenuous unsuccessful labor 3 weeks ago. Family history was negative for ischemic stroke or arterial dissection. The patient was not suffering from common cardiovascular or pregnancy related risk factors like eclampsia or preeclampsia [1]. Cardiac investigations were unremarkable, furthermore coagulopathies have been excluded. MR- (Fig. 1), conventional and duplex ultrasound angiographic imaging revealed a dissection of the right internal carotid artery as well as two separated dissections of the proximal and distal left internal carotid artery, resulting in an occlusion of the proximal right internal carotid artery and a contralateral middle-grade stenosis. To rule out a connective-tissue disorder a skin biopsy was performed, which yielded lesions reminiscent of those found in some types of Ehlers-Danlos syndrome [2]. After ablactation oral anticoagulation with phenprocoumon was initiated and continued over 6 month. Two years later with complete recanalisation of the left ICA and persistent right-sided carotid-artery occlusion a second pregnancy was accomplished. Despite the mothers extensive concerns she was carrying out the child to term under close surveillance with ultrasound. Finally again a caesarean section was performed without any complications.

The association between cerebral ischemia and pregnancy has long been recognized. Furthermore, stroke related with pregnancy is characterized by significant morbidity and mortality [1, 3]. Jaigobin and

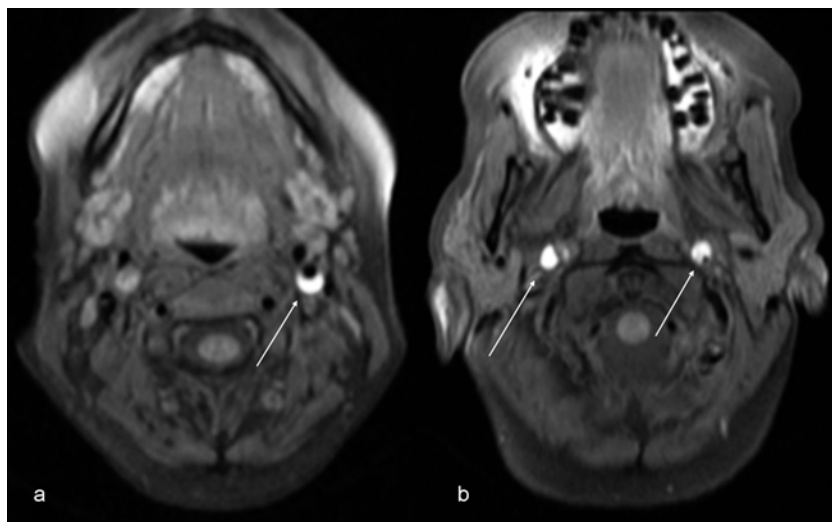


Fig. 1. Fat suppressed axial MR images: a: Proximal dissection of the left internal carotid artery, b: Distal bilateral internal carotid artery dissections.

colleagues conducted a retrospective analysis of patients diagnosed with stroke during pregnancy and childbirth and found 13 of 34 patients to suffer from arterial infarctions, but there was no evidence of dissection [1]. The occurrence of carotid dissection related to pregnancy and childbirth has occasionally been described [4, 5]. Wiebers et al. reported a woman who developed a left cerebral infarction secondary to internal carotid artery dissection after childbirth. Etiologically oral contraceptives have been implicated as one cause for dissection as well as hemodynamic and hormonal changes, resulting in an increased tendency of aneurysms-development and even rupture with advancing gestational age [4], but there have been no case-control studies. In our patient a skin biopsy detected connective tissue changes that were reminiscent of those found in Ehlers-Danlos syndrome. Such changes are well known in pregnant women with preterm premature rupture of membranes [2] and might represent hormonal implicated connective tissue changes during pregnancy. It could be speculated that these hormonal changes have led to a transient vasculopathy [2], although there is no clear evidence separate from the changes in the skin biopsy. Furthermore it is possible that the strenuous labor was the trigger for dissection. To our knowledge, this is the first description of a pregnancy related internal carotid artery dissection and a second uncomplicated pregnancy and childbirth. Although the case of dissection relapse may be a rare event, we feel gestational guidance for patients already have been suffering from dissection during pregnancy to be extremely difficult. However, due to the probably higher risk of recurrent

events a close vascular monitoring should be performed to detect potentially developing vascular affections as soon as possible. However, dissections even associated with connective tissue disorders in antecedent gravidity should, in our opinion, not necessarily lead to a general rejection of further conceptions.

REFERENCES

1. Jaigobin C, Silver FL: Stroke and Pregnancy. *Stroke* 2000; 31:2948-2951.
2. Hermanns-Le T, Pierard G, Quatresooz P: Ehlers-Danlos-like dermal abnormalities in women with recurrent preterm premature rupture of fetal membranes. *Am J Dermatopathol* 2005;27:407-10.
3. Bogousslavsky J, Pierre P: Ischemic stroke in patients under age 45. *Neurol Clin* 1992;10:113-124.
4. Wiebers DO, Mokri B: Internal carotid artery dissection after childbirth. *Stroke* 1985;16:956-959.
5. Bruninx G, Roland H, Matte JC, Magemans H, Jacquy J, Delcour C: Carotid dissection during childbirth. *J Mal Vasc* 1996;21:92-4.

Received: June 1, 2007 / Accepted: March 11, 2008

Address for correspondence:

Hans-Jürgen Gdynia, M.D.
University of Ulm, Dept. of Neurology
Oberer Eselsberg 45
89081 Ulm, Germany
Phone: +49-713-177-5225
Fax: +49-731-177-1202
Email: hans-juergen.gdynia@uni-ulm.de